

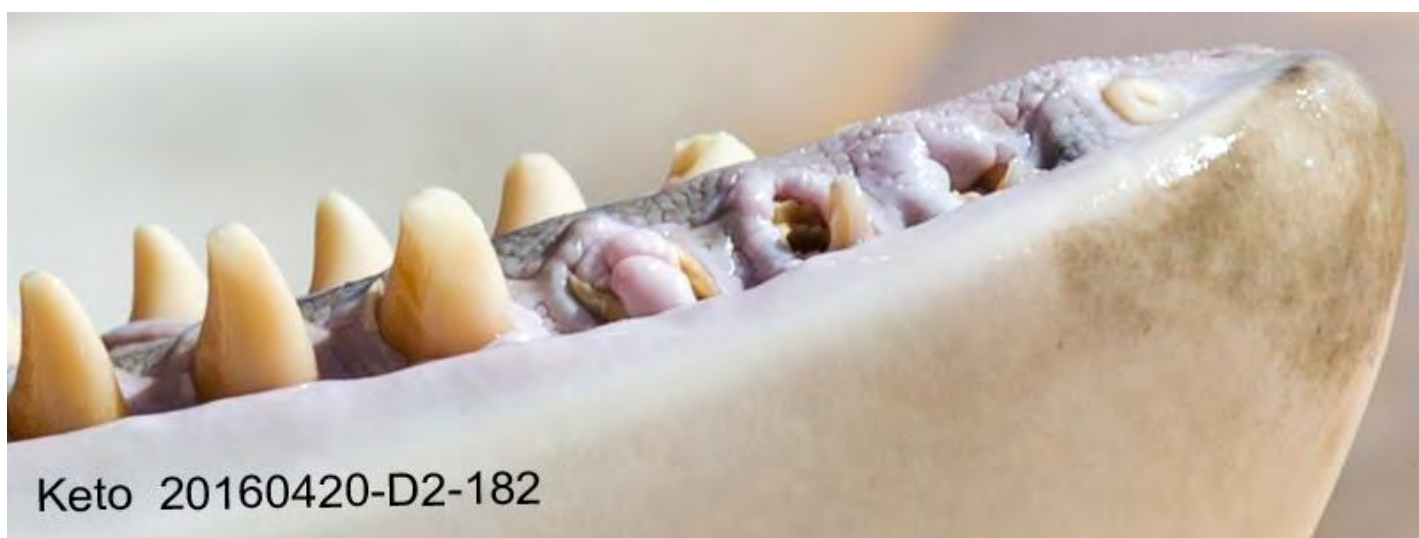# ONGOING CONCERNS REGARDING THE *SEAWORLD* ORCA HELD AT *LORO PARQUE*, TENERIFE, SPAIN

by Dr Ingrid N. Visser & Rosina B. Lisker

([info@freemorgan.org](mailto:info@freemorgan.org))

for the Free Morgan Foundation (15 July 2016)

[www.freemorgan.org](http://www.freemorgan.org)



**Figure 1.** Graphic dental damage on the captive-born *SeaWorld* orca known as Keto. Photo taken at *Loro Parque*, Spain, from the public viewing area, just prior to a circus-like show.

(numbers embedded on picture indicate date (yyyymmdd) & file number)

## EXECUTIVE SUMMARY

Despite assurances by *Loro Parque* that ‘all is well’ with the *SeaWorld* owned orca (killer whales) which are held at their facility, the data gathered here is once again indicative that there are underlying and fundamental issues resulting in the animals suffering and compromised welfare.

A visit to *Loro Parque* (20-22 April 2016), to investigate ongoing concerns, indicated that issues raised previously were at the very least still in effect, or have escalated dramatically.

All observations of the orca were made from public areas and were therefore restricted to the brief scheduled periods of the theatrical circus-like shows. Various indicators were identified during these short observational timeframes which highlights the severity of the issues noted. Repeated ‘snapshots-in-time’ such as these, which continue to capture indicators of poor orca welfare, suggest a deep rooted series of triggers indicative of chronic stressors that are compromising the orca’s welfare. The very indicators identified by the captivity industry as markers for compromised welfare are prevalent and excessive at *Loro Parque*.

One in particular, is of grave concern. The state of the animals’ dentition is easily documentable and as such we could compare a ‘Health Assessment’ by a veterinarian, to photographs taken less than seven months later. Scrutiny of those photos identifies that the youngest orca has had at least eight teeth drilled in this short period. The other five orca have had at least 14 teeth drilled and at least 16 teeth have broken. Alarming, between 41.66% and 75% of their mandibular (lower jaw) teeth were severely damaged. Such permanent self-mutilation and injuries from drilling the teeth are a reflection of extremely compromised welfare standards for orca held at *Loro Parque*.

Furthermore, the staff regularly confine the orca in a tank so small it prevents natural body postures and normal behaviour. Such confinement, which is not associated with medical or husbandry needs, disregards commonsense and welfare guidelines and is against industry ‘best practice’ standards. Violations of at least four of the ‘Five Freedoms’ and 23 published cetacean-specific welfare indicators were noted. Evidence for these was collected in only an extremely truncated timeframe; during the public circus-like shows from merely three days of observations.

Legitimate concerns about the welfare of the orca at *Loro Parque* have been well documented, but remained unheeded over a period of years, leaving the orca exposed to ongoing risk. It is imperative for these animals to be provided with better living conditions that address these welfare issues. Ensuring that welfare standards are met and maintained requires a transparent, independent assessment conducted by experienced authorities who are external to any political influence.

## REGARDING LINKS TO EXTERNAL SITES

To ensure that links to external sites remain accessible and unchanged, they have been archived through the Internet Archive webportal <https://archive.org/web/> . This site collaborates with institutions, including the Library of Congress and the Smithsonian to provide the ability to search and reference digital content as it appeared on a certain date. External links provided herein are preceded by the following prefix: [https://web.archive.org/web/\[date of archive & unique identifier\]/](https://web.archive.org/web/[date of archive & unique identifier]/) .

This prefix is then followed by the original website link. To view the link from outside the Internet Archive, just copy and paste the link from footnote, *sans* the prefix and paste directly into your internet browser.

## Contents

EXECUTIVE SUMMARY .....	2
REGARDING LINKS TO EXTERNAL SITES .....	3
HOW TO CITE .....	3
FIGURES, TABLES & APPENDICES LIST.....	4
1. TEETH .....	5
2. WELFARE INDICATORS .....	30
3. INAPPROPRIATE USE OF THE MEDICAL TANK & LACK OF SHADE .....	34
4. BREEDING.....	45
5. MORGAN.....	45
6. KETO .....	52
7. CONCLUSIONS .....	59
REFERENCES .....	66

## HOW TO CITE

Visser, I. N. & Lisker, R. B. (2016). Ongoing concerns regarding the *SeaWorld* orca held at *Loro Parque*, Tenerife, Spain. Unpublished report. 67 pages. Available from [www.freemorgan.org](http://www.freemorgan.org)

## FIGURES, TABLES & APPENDICES LIST

<b>Figure 1.</b> Dental damage on SeaWorld orca, Keto, at <i>Loro Parque</i> .....	1
<b>Figure 2.</b> Fish, ice and gelatine do not touch the teeth of an orca fed in captivity .....	6
<b>Figure 3a-d.</b> Adán, male, born 13 October 2010 ( <i>i.e.</i> , 5 years, 6 months old), teeth .....	12-13
<b>Figure 4a-b.</b> Morgan, female, wild-born (approx. 9 years old), teeth .....	15
<b>Figure 5.</b> Timeline of damage Morgan's teeth .....	17
<b>Figure 6a-f.</b> Skyla, female, born 09 February 2004 ( <i>i.e.</i> , 12 years, 2 months old), teeth .....	21-23
<b>Figure 7a-d.</b> Kohana, female, born 03 May 2002 ( <i>i.e.</i> , nearly 14 years old), teeth .....	24-25
<b>Figure 8a-d.</b> Tekoa, male, born 08 November 2000 ( <i>i.e.</i> , 15 years, 6 months old), teeth .....	26-27
<b>Figure 9a-e.</b> Keto, male, born 17 June 1995 ( <i>i.e.</i> , 20 years, 10 months old), teeth .....	28-30
<b>Figure 10.</b> Sign at <i>Loro Parque</i> ; Animal welfare standards for the "Five Freedoms" .....	32
<b>Figure 11a-b.</b> Layout of the tanks at <i>Loro Parque</i> , Tenerife, Spain .....	39
<b>Figure 12a-b.</b> Morgan on the raised floor of the medical tank at <i>Loro Parque</i> .....	40
<b>Figure 13.</b> Tekoa and Kohana in medical tank in 2013. The floor is raised and they cannot swim ..	41
<b>Figure 14.</b> Sign at Orca Ocean stadium, indicating maintenance conducted 4 April-21 May 2016 ...	41
<b>Figure 15.</b> Water drained & paint scheme of the walls of the 'Orca Ocean' west tank .....	42
<b>Figure 16.</b> Medical tank segregation gates constructed with heavy pipe-metal .....	42
<b>Figure 17.</b> Morgan, Tekoa and Adán all in the medical tank together .....	43
<b>Figure 18.</b> Morgan with mucus streaming from her eye, while locked in the medical tank .....	43
<b>Figure 19.</b> The orca at <i>Loro Parque</i> were frequently photographed with their eyes closed .....	44
<b>Figure 20.</b> Tekoa with the remains of a white substance on his melon and rostrum .....	44
<b>Figure 21a-c.</b> Morgan 'lunging' out of water .....	46-47
<b>Figure 22.</b> Rake marks (from orca teeth) on Morgan's left eye patch and ventral area .....	48
<b>Figure 23.</b> Morgan skin drying out whilst she is hauled out on ledge .....	49
<b>Figure 24.</b> Tekoa hauled out on the ledge surrounding the east tank at <i>Loro Parque</i> .....	49
<b>Figure 25a-b.</b> Morgan attempting to chew on the concrete .....	51
<b>Figure 26a-d.</b> Keto, skin sloughing around & under dorsal fin .....	53
<b>Figure 27a-b.</b> Keto, swimming, showing sloughing skin anterior to dorsal fin .....	54
<b>Figure 28a-b.</b> Keto, 'pock marks' on the paler pigmentation of his saddle patch .....	55
<b>Figure 29a-b.</b> Keto, two patches of roughed skin on his right caudal peduncle .....	56
<b>Figure 30a-d.</b> Keto, lateral thorax area (above the pectoral fin insert) showing 'wrinkled' skin .....	57-58
 <b>Table 1.</b> Morphological descriptions of damage to orca teeth .....	 9-10
<b>Table 2.</b> Summary of breaches of minimal animal welfare standards, by <i>Loro Parque</i> .....	33
<b>Table 3.</b> Comparison of tank sizes to Morgan's size .....	35
 <b>Appendix 1.</b> Summary, damaged teeth of the six orca held at <i>Loro Parque</i> .....	 60
<b>Appendix 2.</b> Details of dentition of orca, comparisons between inspection & documentation .....	61-63
<b>Appendix 3.</b> Ranking of tooth damage and % of dental damage to mandibular teeth .....	64
<b>Appendix 4.</b> Clegg et al (2015) welfare indicators for captive bottlenose dolphins .....	65

## 1. TEETH

The most graphic and undeniable welfare indicator for captive orca is the damage they sustain to their teeth (e.g., such as that illustrated in the cover image, Figure 1). Unfortunately, the captivity industry tries to frame the dental damage sustained in their facilities as ‘normal’. Such obtuse allegations are easily and logically dispelled.

The captivity industry has attempted to compare the extreme damage seen on their orca to the natural damage seen on some free-ranging (wild) populations of orca. For instance *SeaWorld* states on their ‘SeaWorld Cares’ website; “Killer whales [orca], like all toothed whales and dolphins, develop worn teeth. It's important to note that wild killer whales wear their teeth as well. And just like our killer whales, it's a result of exploring and manipulating things in their environment.”<sup>1</sup> And on the same page they state “They use their mouths to manipulate their environment.” However, to be clear, there is no published scientific research that discusses or describes wild orca “manipulating things” or that wild orca “manipulate their environment” with their mouths. Conversely, published peer-reviewed articles, by captivity industry experts, recognise that the source of damage to captive orca teeth is the hard surfaces in the tanks (Graham & Dow 1990, Ventre & Jett 2015).

Although some populations of orca may feed on large prey which have ‘hard’ bones, such as the Argentinean orca who feed on sealions (Lopez & Lopez 1985, Hoelzel 1991, Iñíguez *et al.* 2002), those populations do not show tooth damage like that found systemically throughout the orca held in captivity<sup>2</sup>.

In another attempt to frame the dental damage as ‘normal’, the captivity industry claims variations on the theme that it results from; the way the animals manipulate their food; the animals feeding methods; or that in captivity the food (fish and squid) they are fed are causing this dental damage<sup>3</sup>. It appears that the captivity industry has conveniently overlooked the fact that all toothed whales, dolphins and porpoises (cetaceans) have teeth of similar shape (termed homodont dentition) (Loch *et al.* 2013) and typically do not chew (masticate) their food, but rather rely on ‘ram’, ‘suction’ or ‘raptorial’ feeding methods (Werth 2000). In the wild, although cetacean teeth are important in food acquisition through grasping, they typically have extremely limited function in food processing.

In the case of orca, some populations forage on large prey such as other marine mammals (Baird 1987, Ford *et al.* 1998) and those orca would manipulate their food when tearing off sections (Barrett-Lennard *et al.* 2011). However, these types of orca have likely evolved and adapted to cope with such stressors on their skull and morphology dentition. For example, the Pacific population known as ‘transients’, who forage on marine mammals, have skulls which are more robust and teeth which are much larger and more robust than other populations (Wilson, S. pers. comm.). Transients do not typically show excessive tooth wear (e.g., see photo of one male (at least 10 years old) and one female (at least 20 years old) in Ford & Ellis 1999, and see Figure 3 and Table 3 in Ford *et al.* 2011, as well as their supplementary material).

One population known as ‘offshore’ orca, found in the north Pacific, are recognised to have population-wide tooth wear. This has been attributed “at least in part due to abrasion from dermal denticles embedded in shark skin” – a type of prey that is postulated as their main food source (Ford *et al.* 2011). However, it should be recognised that the five *SeaWorld* orca held at *Loro Parque* were all born in captivity and are all hybrids from different fish-eating populations (Jett & Ventre 2015 and see [www.orcahome.de](http://www.orcahome.de)

<sup>1</sup> <https://web.archive.org/web/20160708185331/https://ask.seaworldcares.com/en/?q=teeth>

<sup>2</sup> <https://web.archive.org/web/20160708223111/http://www.pnor.org/site/en/>

<sup>3</sup> <https://web.archive.org/web/20160621171126/http://blog.loroparque.com/statement-lp/?lang=en>



and [www.ceta-base.org](http://www.ceta-base.org)). Although a North-Atlantic population of orca (termed Type 1 by Foote *et al.* 2009) has been described as having diagnostic population-wide tooth-wear, those orca despite sharing some genetic haplotypes with fish-eating Norwegian orca, are postulated to be very generalist feeders who also take marine mammals (Foote *et al.* 2009). Morgan, a wild-born orca, held at *Loro Parque*, is also from a fish-eating population of orca (from Norway) and that population has not historically been recognised as having extreme tooth wear (Christensen 1982, Christensen 1984).

It is important to note that the extreme damage observed in the teeth of all captive orca cannot occur due to feeding in the nonsensical way the industry describes, because trainers feed them by dumping handfuls of fish directly into the back of their mouths. Such feeding usually happens whilst the orca are stationed (commanded to remain in position) and the fish rarely, if ever, touch the teeth. The teeth, are therefore not used to capture or grasp their food, nor are they involved in food manipulation. Likewise, ice and gelatine which are given to the orca in attempts to alleviate dehydration due to inadequately hydrated food<sup>4</sup>, are typically delivered in the same way by dumping into the back of the mouth (*e.g.*, Figure 2). The Type 1 orca described above with tooth-wear, are postulated to use suction feeding – again, not something that occurs in the captive orca due to the method of, for lack of a better term what we have come to call, ‘dump-feeding’, used by trainers.



**Figure 2.** Two examples of the typical feeding method for orca in captivity; a handful of fish is dumped into the back of the mouth of a ‘stationed’ orca. The fish (and ice) do not touch the animal’s teeth and the fish are so small that no food manipulation is required. Note dropped fish on floor in both photographs and cubes of red gelatine in corner of the mouth of ‘Keto’, left.

This leads to the logical conclusion that mechanical wear from the orca chewing against hard surfaces, such as metal bars, metal plates, concrete surfaces etc., is the primary reason for such damage. Normally, it would go without saying - but apparently needs to be stated given the atmosphere of the industry’s claims - that drilling of teeth and the subsequent daily required irrigation does not happen within, or to, any wild orca populations. Drilling had to be done by the facility staff solely because of the damage the orca sustained whilst in captivity and irrigation is required because of the holes which are left unfilled.

Although, it is recognised that damage is sometimes created by the orca violently slamming their jaws together in what is often termed ‘jaw popping’ or ‘jaw clapping’ (Ventre & Jett 2015). This action, a

<sup>4</sup> <http://www.seaworldfactcheck.com/food.htm>

precursor to aggression, is often seen in captivity due to the inappropriate social groupings imposed on the animals. It is further exacerbated by the inadequate spaces the animals are forced into which creates unnecessary social tensions and further stress (Section 3. INAPPROPRIATE USE OF THE MEDICAL TANK).

There is extremely limited scientific literature available regarding the issues of captive orca teeth as the industry has not published in detail about this detrimental aspect of orca welfare. Despite this, there are three papers that do highlight the issue, albeit that only the first is specifically about orca dentition; Graham & Dow (1990), Jett & Ventre (2012) and Ventre & Jett (2015). All three papers note that concrete tanks and/or metal segregation gates create dental stress for captive orca. Such stress includes apical (tip) wear (at times severe enough to wear the teeth to the gum, despite the fact that approximately 1/3 of the tooth erupts above the gum line), chipping, cracks and fractures.

The apical damage seen on captive orca often becomes so extensive that it results in life-threatening damage, which the facilities attempt to mitigate by drilling. Once the teeth are drilled they lose their structural integrity. At that point, further chewing on hard surfaces stresses the already compromised teeth which then typically chip, fracture, break, implode (collapse) or have to be removed completely (see Table 1 for examples of these). To classify captive orca tooth damage at *Loro Parque* we compiled 16 categories, all which were photographed on at least one of the orca held at that facility (Table 1).

In cetaceans only one set of teeth is produced and none are replaced if lost or damaged. It is of note that unlike most other calcified skeletal elements (*e.g.*, bones), such damage does not naturally repair and as such remains as a permanent record, unless masked by further damage. Most of the enamel in toothed cetaceans is laid down before birth (Boyde 1980), although in most species dentine forms in layers for the duration of their life and is presumed to be deposited yearly (Perrin & Myrick 1980).

Another erroneous claim made by the industry (in this case *Loro Parque* themselves) is that “*The teeth of these animals [orca] are much weaker and tend to wear away faster than other terrestrial carnivores*”<sup>5</sup> [emphasis added because orca are not terrestrial (they are obviously 100% aquatic) and although some populations (ecotypes) are carnivores many populations are piscivores (fish eating)]. Such unsubstantiated and deceptive claims are unfortunate as they misinform the public. However, they can be plainly refuted. Scientific research has shown that orca teeth are harder than the teeth of cattle (terrestrial herbivore) and sand tiger sharks (aquatic carnivore/piscivore) (Figure 4.3 in Loch Santos da Silva 2013). Furthermore, when orca teeth were compared to nine other dolphin species they were found to have the second **hardest** average enamel (Loch et al. 2013). Scientific research has also shown that there is no significant difference in the hardness value between the buccal (lip) and lingual (mouth) surface of orca teeth (Loch et al. 2013) despite the wear on captive orca teeth being excessive on the buccal surfaces.

In captivity, this excessive buccal damage occurs despite the fact that the ‘lips’ of orca are extremely rigid to the point of being relatively unyielding to substantial pressure, *i.e.*, they are ‘stiff’ (Visser, unpublished data). Orca ‘lips’ are therefore distinct from the flexible ‘lips’ that humans generally associate with mammals (Bolwig 1964, Waller & Micheletta 2013). The rigidity of the upper ‘lips’ all but eliminates the buccal surfaces of orca teeth from coming into contact with their food, even if the prey was manipulated. Thus, based on enamel hardness and ‘protection’ by the lips (particularly in the maxillae), it is unreasonable and imperceptive to even attempt to propose that the damage seen on captive orca teeth is due to feeding.

<sup>5</sup> <https://web.archive.org/web/20160629035358/http://blog.loroparque.com/statement-lp/?lang=en>

The issue of dental damage and dental stressors at *Loro Parque* has been raised multiple times (e.g., see Visser (2012) and documents presented during court cases<sup>6</sup>). For at least the past four years, with mounting evidence of excessive dental damage and therefore compromised welfare for the *SeaWorld* orca held at *Loro Parque*, multiple requests by stakeholders have been made for an inspection(s). One of the orca held at *Loro Parque* is wild-born and is known as Morgan (Visser 2012). She is of particular concern because of her provenance and dispute over her ownership (Spiegl & Visser 2015). In one instance it was suggested by stakeholders that a mutually agreed upon veterinarian, as well as a Judicial Officer, be used. However, these requests were met with disdain by *Loro Parque*'s owner, Mr Wolfgang Kiessling and were denied<sup>7</sup>. Outlandishly, despite the physical evidence clearly to the contrary (and the health assessments conducted by *Loro Parque* contracted veterinarians), Mr Kiessling stated on 30 September 2013 "*There is no concern about Morgan's health.*"<sup>8</sup> and *Loro Parque*'s official blog used exactly the same words on 28 April 2016.<sup>9</sup>

To validate the concerns raised by the stakeholders, including the Free Morgan Foundation (FMF) ([www.freemorgan.org](http://www.freemorgan.org)), observations by the authors of this report (Visser & Lisker) were made at *Loro Parque* 20-22 April 2016. This included photographing (where possible) the open mouths of the orca. It is worth noting that all images contained herein were taken from the public viewing areas (typically from 15m (49ft) to more than 80m (262ft) from the orca in question) and only during the public viewing (show) times. As such, the images are not necessarily of similar angles for each orca, nor in sharp focus. Also, the mandibles (lower jaws) tended to be photographed more frequently than the maxillae (upper jaws), therefore we predominantly discuss the teeth on the mandibles.

On 29 September 2015, veterinarian Dr Andrew Greenwood prepared a "*Health and welfare assessment of the killer whale group held at Loro Parque, Tenerife.*"<sup>10</sup> (hereafter referred to as the 'Health Assessment' report). His report, which covered the five orca owned by *SeaWorld* and the wild-born orca known as Morgan, is barely three pages long. It only includes a maximum of two paragraphs for each orca and within those brief statements Dr Greenwood comments on a wide range of aspects, including each orca's behaviour (during shows and outside of them) and their physical condition including weight, rake marks (bites from other orca), skin, eyes and dentition.

Although the 'Health Assessment' makes reference to additional '*Health and management records*', of which Greenwood states; "*I reviewed the records for each animal for the last two years*", he makes no reference to any detailed dental records nor any description of how dentition is assessed. If such dental records do exist and if they document the issues to the extent illustrated herein (e.g., see Figures 3-9 and Appendices 1 & 2), those records would make the 'Health Assessment' report, as well as the statements by Dr Javier Almunia and the two veterinarians (see page 16, paragraph 1 herein), even more troubling.

<sup>6</sup> Documents from the court cases can be found at <http://www.freemorgan.org/evidence-for-court/>

<sup>7</sup> Correspondence available from the authors upon request





<sup>8</sup> <http://www.freemorgan.org/wp-content/uploads/2016/07/20130930-Kiessling-refusal-for-inspection-R.pdf>

<sup>9</sup> <https://web.archive.org/web/20160621171226/http://blog.loroparque.com/2016/04/?lang=en>


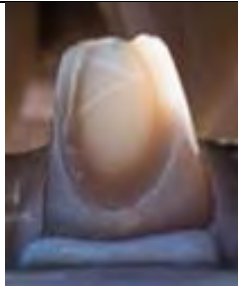




<sup>10</sup> <http://www.freemorgan.org/vet-inspections/>



**Table 1 (Part I & II – OTHER & BROKEN).** Morphological descriptions of damage to orca teeth. Examples from *Loro Parque* between 20-22 April 2016\*. Descriptions apply equally to both maxillae (upper) and mandible (lower) teeth. Damage increases in harm from left to right. The categories are not mutually exclusive, *e.g.*, see the first tooth in Part II (Broken) which is ‘Broken’, ‘Cracked’, but it is also ‘Drilled’ and ‘Nearly worn to gum’. A collapsed tooth is likely to have had ‘Severe’ apical wear (i.e., to point that the pulp was exposed), was then ‘Drilled’, may have been ‘Worn to gum’ and with subsequent mechanical wear from chewing on hard surfaces, then ‘Fractured’ and finally ‘Collapsed’.

<b>PART I. OTHER</b>			
<b>Undamaged</b> = no apparent wear, cracks, or other damage. CATEGORY = UNDAMAGED	<b>Vestigial</b> = tooth (1cm (0.39 in) or less total length) appears, previously embedded under gum and excessive wear of gum exposes tooth, may or may not be damaged. CATEGORY = SEVERE	<b>Protrudes</b> = tooth protrudes into gum, gum is impacted more than tooth, tooth may or may not be damaged. CATEGORY = MINIMAL	<b>Missing</b> = tooth completely gone, gum may appear ‘puckered’ & show gap or may completely cover over the hole. * CATEGORY = SEVERE
			


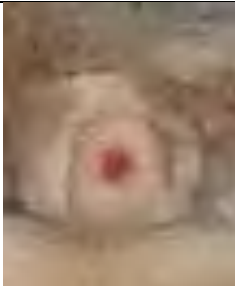


\* this photograph was taken at *Loro Parque* during 2013, although the issue persists in 2016.





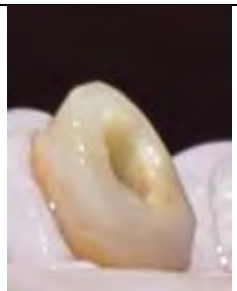



<b>PART II. BROKEN</b>			
<b>Cracked</b> = split in tooth, may be in enamel only or run deeper into enamel-dentine juncture. CATEGORY = SEVERE	<b>Chipped</b> = part of the tooth broken off (location described). CATEGORY = SEVERE	<b>Fractured</b> = broken in half, or splintered into parts; most of tooth still visible (compare to Collapsed). Typically drilled before fracturing. CATEGORY = SEVERE	<b>Collapsed</b> = the tooth has imploded into the gum, some parts of the tooth may still be visible or upright. Gum may intrude into or over tooth. Typically drilled before collapsing. CATEGORY = SEVERE
	 		 

Descriptions of tooth wear, continues....

**Table 1. (Part III & IV – DRILLED & APICAL WEAR).** Morphological descriptions of tooth wear.

See above caption for full details.

PART III. DRILLED			
<p><b>Likely drilled</b> = small hole visible, likely the result of drilling (medical records would confirm). CATEGORY = SEVERE</p>	<p><b>Pulp</b> = inner soft area of tooth may be exposed or visible from drilling, or a 'pulp spot' may visible where apical wear has nearly exposed pulp. Pulp may appear red or blood may be visible. CATEGORY = SEVERE</p>	<p><b>Drilled</b> = hole drilled into the tooth (pulp appears to have been debrided). CATEGORY = SEVERE</p>	
	 		

PART IV. APICAL WEAR				
<p><b>Starting</b> = tip of tooth showing some wear. CATEGORY = MINIMAL</p>	<p><b>Moderate</b> = most of tip of tooth worn, but general shape still discernible, no pulp (or pulp spot) visible. CATEGORY = MODERATE</p>	<p><b>Severe</b> = pulp of tooth (or pulp spot) visible, drilled or likely drilled. An extreme angle of wear may result in part of the tooth being worn nearly to, or to, the gum but tooth still classified as 'severe'. CATEGORY = SEVERE</p>	<p><b>Nearly to gum</b> = tooth has been worn nearly level with the gum. Most teeth that have been nearly worn to the gum have been drilled at some stage, but holes may no longer be visible or appear smaller. CATEGORY = SEVERE</p>	<p><b>To gum</b> = tooth worn to the gum. Most teeth that have been worn to the gum have been drilled at some stage, but holes may no longer be visible or just appear as 'dimples'. CATEGORY = SEVERE</p>
		 	 	 

In general the Greenwood 'Health Assessment' lacks substantive details regarding much about the health of the animals and instead, just a general description is given. For example, when reporting about Adán, Greenwood's unabridged entry for this animal (page 2) reads;

*"The young male born at Loro Parque, weight 1036 kg., in excellent condition. He had one patch of recent rake wounds on one side, otherwise his skin was in good condition. His eyes were clear and of normal appearance. **Several teeth in his lower jaw showed wear down to the pulp level, but only one had been drilled open, the rest being still vital. One tooth was broken.** Adan was very active in the pool, but did not take part in the display."* [emphasis added]

If the reader remains focused only on the state of dentition for this animal, it is abundantly obvious that these two sentences do *not* accurately indicate which teeth (left or right) were worn, nor which tooth (typically identified by counting from the anterior of the mouth and indicating maxillae or mandible and left or right), had been drilled open, nor which tooth was broken. It does not indicate that the 'broken' tooth is completely fractured into parts and that it had previously been worn to the gum and that it had also been drilled. A more accurate description of Adán's teeth (for the left mandible only), is given by Visser & Lisker (herein, caption Figure 3b);

*"....tooth (mandible L1) is worn to gum and at least two teeth (mandible L2, L3) have substantial holes, have been drilled and both are worn to the gum. Furthermore, another tooth (mandible L4) appears to have been previously drilled, but is now fractured and splintered into parts, is worn to the gum and has gum overgrowth. One tooth (mandible L5) has a smaller hole at what is now the apex, indicative of drilling and also has severe apical wear. The tooth (mandible L6) has moderate wear as the apical section is worn off."*

Less than seven months passed between Greenwood's inspection (29 September 2015) and when Adán was photographed by Visser & Lisker (20 April 2016). The extreme acceleration of dental damage sustained between these two events is **eight more teeth drilled and six more worn to the gum**. Details are summarised in Appendix 1 and given in detail in Appendix 2. Although Dr Greenwood may mention teeth that are drilled he fails to explain or note that these drill holes are then left open and must be flushed daily to prevent impacted food from becoming a hazard (e.g., infections due to rotting fish).

Within such a compressed timeframe we have documented acute levels of dental stress for Adán and the other five orca, which signify and illustrate (not only to a layperson but to anyone with any ethical scruples or moral integrity), that there are major and unacceptable welfare issues associated with the keeping of orca in captivity at *Loro Parque*. There is a duty and an obligation to fix the problems as clearly this species does not thrive in captivity. To deny there are issues in the light of this evidence would be irresponsible as well as inhumane.

In each case where clear photographs could be obtained, the images contained evidence of extreme dental issues (Figures 3-9). The case studies of the orca at *Loro Parque* are presented in ascending age and each photograph has the date (yyyymmdd) and the file number embedded on it, along with the animals' name, to help facilitate cross referencing. Additionally, in the caption of figure (b) for each animal, the assessment of the teeth of the orca, extracted from the Greenwood 2015 'Health Assessment', is presented. Our assessment and description is then listed for comparison.



**Figure 3a.** Adán, male, born 13 October 2010 (i.e., 5 years, 6 months old). This photograph includes the unique 'eye patch' to facilitate correct identification. Figure 3b shows close up of offending left-side teeth. Note tooth wear on opposing (right) side is partially visible (see Figure 3d for right-side details).

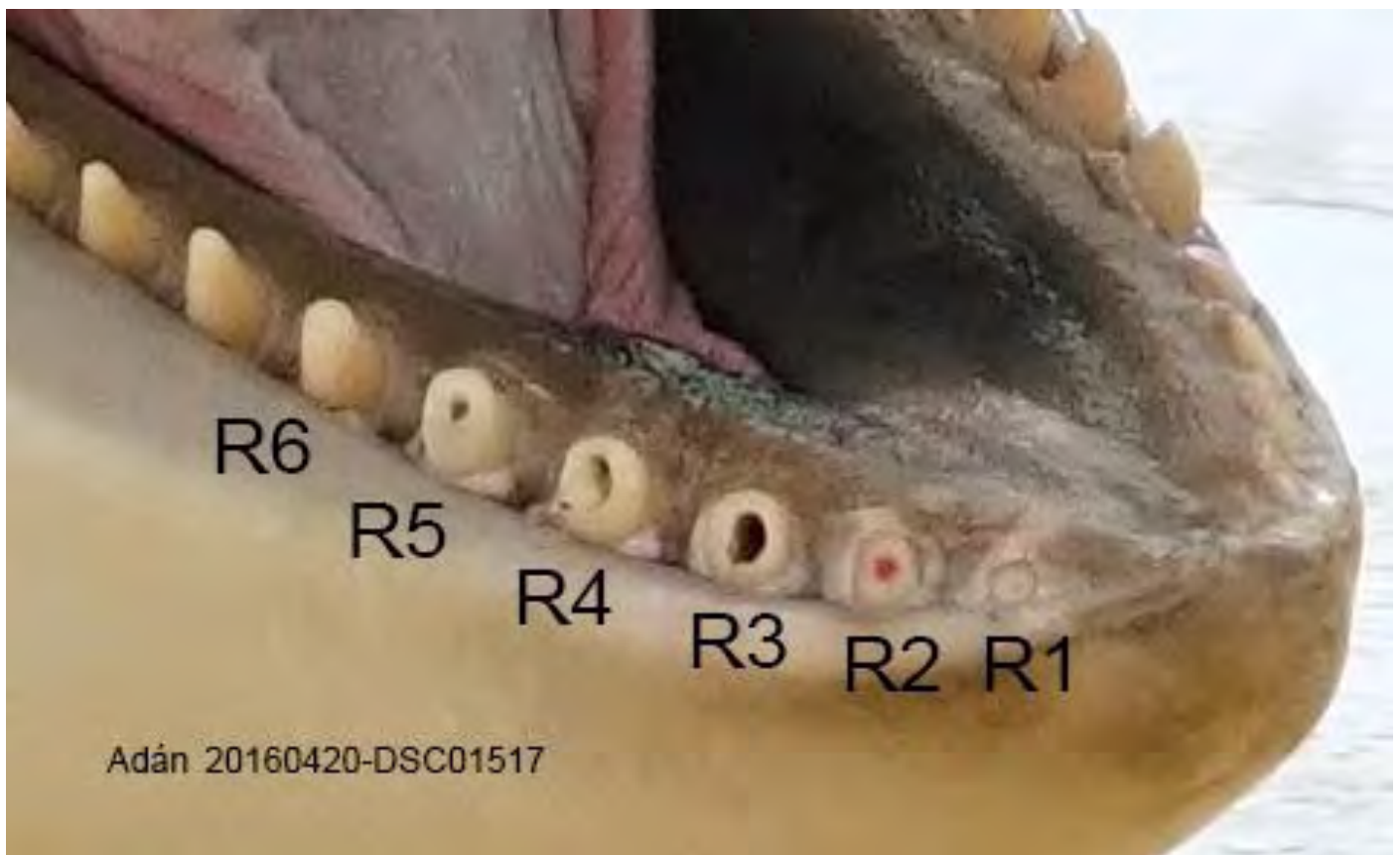


**Figure 3b.** Adán, close up of offending teeth, left side. Note hypertrophic tissue damage (discolouration) to end of the mandibles from self-mutilating stereotypic behaviours (such as banging jaw against concrete). Greenwood (2015) wrote on the 29<sup>th</sup> of September 2015 that he observed Adán and noted; *"Several teeth in his lower jaw showed wear down to the pulp level, but only one had been drilled open, the rest being still vital. One tooth was broken."* It is unclear from this description which teeth Greenwood was referring to (left or right), but regardless; tooth (mandible L1) is worn to gum and at least two teeth (mandible L2, L3) have substantial holes, have been drilled and are both worn to the gum. Furthermore, another tooth (mandible L4) appears to have been previously drilled, but is now fractured and splintered into parts, is worn to the gum and has gum overgrowth. One tooth (mandible L5) has a smaller hole at what is now the apex, indicative of drilling and also has severe apical wear. The tooth (mandible L6) has moderate wear as the apical section is worn off.





**Figure 3c.** Adán, right side. This photograph includes the unique 'eye patch' to facilitate correct identification. Figure 3d shows close up of offending teeth.



**Figure 3d.** Adán, close up of offending teeth, right side. Note tooth wear on opposing (left) side is partially visible (see Figure 3b). Tooth (mandible R1) apparently has small hole, may or may not be drilled and is worn to the gum. Tooth (mandible R2) shows exposed red tissue (pulp) inside a drilled hole and is worn to the gum. Tooth (mandible R3) has been drilled and is nearly worn to the gum. Teeth (mandible R4, R5) have been drilled and have severe apical wear with the buccal edge worn to gum. Tooth (mandible R6) showing moderate apical wear.



Of note is that all orca, except one (Morgan, Figure 4a & 4b), were photographed on both the left and right side. This was because Morgan was typically moved into the medical tank, by *Loro Parque* staff soon after the arrival of Visser & Lisker, to prevent clear photographs being taken. Morgan was typically held in the medical tank with Tekoa, the only other orca who was not clearly photographed on both the left and right side (his left side was photographed more obliquely, from the front of his mouth) (Figure 8c-d). Furthermore, if the authors attempted to stand in the area by the east tank (*i.e.*, still in the general public viewing area) in order to attempt to photograph the distant animals in the medical tank, they were firmly instructed by security staff to move into the stadium area or to leave the facility. This was, again, in an apparent attempt to prevent photography to document Morgan's physical condition.

Despite these actions, even though only Morgan's right side was photographed, Visser & Lisker were able to clearly identify at **least four, possibly five**, fractured teeth. It is unknown if she has more broken or damaged teeth on her left side. Our findings prompted us to express, in writing, our concerns about the evasive nature of the staff. We also stated that such behaviour suggested that *Loro Parque* was trying to hide welfare issues from us. Visser wrote directly to Dr Javier Almunia<sup>11</sup> expressing our concerns about the staff's conduct and requested an inspection of Morgan, which he agreed to. The following day, on 22 April 2016, during the pre-arranged meeting held in the Orca Ocean stadium<sup>12</sup>, Visser & Lisker spoke briefly with Dr Almunia and two veterinarians (names unknown) who were introduced by Dr Almunia as "*the veterinarians conducting the medical care of the orca*" [at *Loro Parque*].

During that meeting (lasting approximately 15 minutes) Morgan was in the main show tank, repeatedly swimming the same pattern across the front of the stage and back through the middle of the tank. She was shadowed extremely closely by Keto, an adult male, who showed an inordinate amount of interest in her. At no time did Morgan show any interest in her surroundings, including trainers walking around the enclosure or our atypical post-show presence. She did not lift her head out of the water and no close-up images of her body or teeth were possible, rendering an inspection impossible. A request by Visser & Lisker, for Morgan to be 'stationed' at the side of the tank to facilitate photography or even a visual assessment was refused by Dr Almunia.

A request by Visser, for a photograph(s) of Morgan's teeth (to be taken by *Loro Parque*) was verbally granted by Dr Almunia and agreed to by both the veterinarians. Dr Almunia also verbally confirmed he would send the photographs by email. A few days later, in writing (pers. comm., Dr Javier Almunia, dated 20160428), he refused to supply the photograph(s) stating; "*Finally, after a consultation to [sic] the management of Loro Parque about the possibility to send you a close up picture of Morgan teeth, they have declined this possibility based on the previous criticism of Free Morgan Foundation against Loro Parque.*"

Of particular note is that during the meeting on the 22 April 2016, Dr Almunia provided Visser & Lisker with the Greenwood (2015) veterinarian 'Health Assessment' report outlined above (as well as a 2013 report by Greenwood)<sup>13</sup>. *Loro Parque*, on their official blog describe these reports as "*the last veterinarian reports made by an independent international veterinarian with over 40 years of experience with Killer whales*"<sup>21</sup>. The 2015 version contains, under the subheading 'Morgan', a brief description of the damage sustained to her dentition that Greenwood observed on 29 September 2015; "*Five teeth in the lower jaw were worn to the pulp level but not drilled out, and **two were broken**.*" [emphasis added].

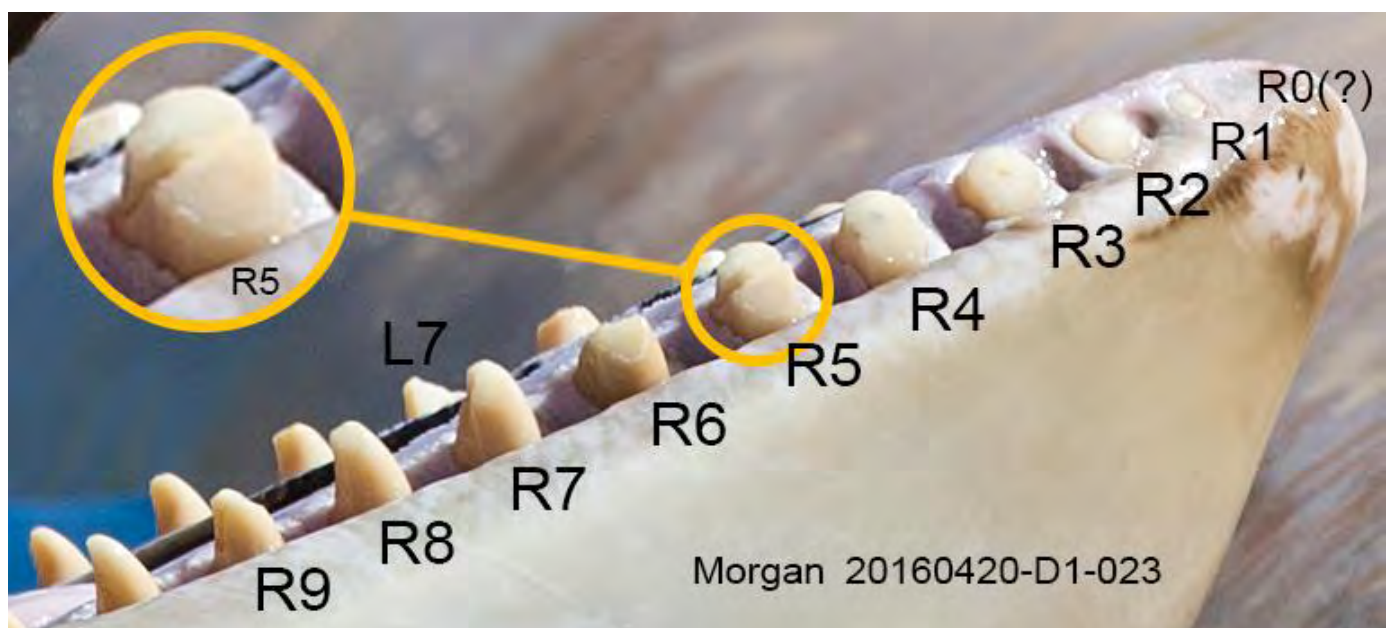
<sup>11</sup> Director of Environmental Affairs, Loro Parque Foundation

<sup>12</sup> <https://web.archive.org/web/20160621171226/http://blog.loroparque.com/2016/04/?lang=en>

<sup>13</sup> <http://www.freemorgan.org/vet-inspections/>



**Figure 4a.** Morgan, female, wild-born (therefore age is estimated, based on size, to be approximately nine years old). This photograph includes the unique 'eye patch' to facilitate correct identification. Figure 4b shows close up of offending teeth of right-side. Note, no detailed photograph of left side was obtained.



**Figure 4b.** Morgan, close up of offending teeth, right side. Additional tooth wear on opposing (left) side is partially visible. Note hypertrophic tissue damage (discolouration with white patches) to the end of the mandibles. Greenwood (2015) wrote that on the 29<sup>th</sup> of September 2015 he observed Morgan and noted; *"Five teeth in the lower jaw were worn to the pulp level but not drilled out, and two were broken."* It is unclear from his description which teeth Greenwood was referring to (left or right), but regardless, at **least four, possibly five**, teeth are now broken. It is unclear if a visible indent in the gum is a very small vestigial tooth (labelled as R0 (?)) worn to the gum or is just an indent, hence labelling starts at zero. Teeth (mandible R1, R2) are worn to the gum, whilst tooth (mandible R3) is likely drilled (a small hole is visible) and is nearly worn to gum. Tooth (mandible R4) has severe apical wear and a 'pulp spot' is visible. One tooth (mandible R5) is broken (fractured and split in half; circled and enlarged) and has moderate apical wear. Another tooth (mandible R6) is broken (chipped) with the lingual (inner) surface missing. Tooth (mandible R7) has a broken off section on the distal (posterior) surface and has moderate apical wear. Tooth (mandible R8) shows moderate apical wear. Tooth (mandible R9) is broken (chipped, distal surface) and/or has moderate apical wear. Additionally, on the left jaw, teeth (mandible L1, L2, L3, L4, L5, L6) have at least severe apical wear. Tooth (mandible L7), is broken lingually and/or mesially (anteriorly) and has moderate apical wear. Tooth (mandible L8) shows moderate apical wear. See Figure 25 documenting her tooth degradation over time.

Given this written documentation by Greenwood and our photographic evidence from two days before the meeting, Visser specifically asked Dr Almunia and the two veterinarians about Morgan's teeth and explicitly the fractured tooth circled and enlarged in Figure 4b (i.e., tooth mandible R5). All three employees denied that Morgan had any broken teeth. Subsequent to the authors' visit, on 28 April 2016, *Loro Parque* posted on their official blog website the following text; "*Dr. Visser asked about Morgan's broken teeth, and the veterinarian staff confirmed that Morgan does not have broken teeth just abrasion in [sic] some of them.*" [emphasis added].

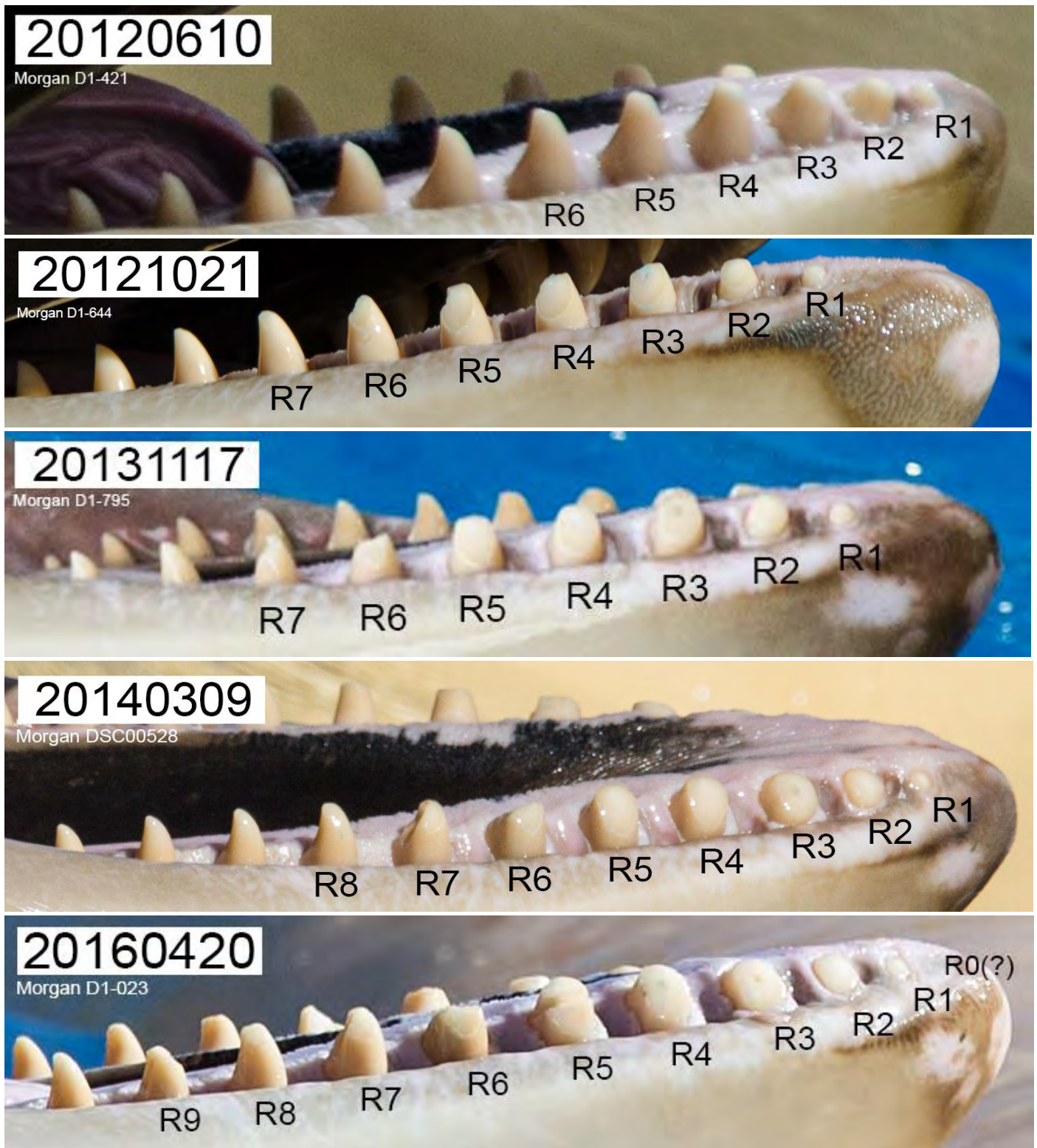To put the damage sustained by Morgan into a framework as teeth are 'measurable' and 'documentable', a timeline of the self-mutilation and destruction of her teeth at *Loro Parque* has been compiled and is presented in Figure 5. If just a single tooth (mandible R5, for example) is tracked through these images the damage sustained becomes unequivocal. The tooth damage increased from having the start of apical wear in June 2012, to having moderate apical wear and being broken (chipped, distal surface) on four months later. The wear continued over the next year, to the point that the wear on the buccal surface was nearly to the gum. Then, at some point between March 2014 and April 2016 this same tooth was fractured into at least two parts.

It is very clear from this series of images that Morgan suffers from relentless compromised welfare as the number of damaged teeth illustrates. If only assessing her teeth on the right mandible, rate of damage continues to escalate as Morgan went from having minimal apical wear on six teeth to having severe apical wear on five teeth, one of which was broken teeth and an additional five broken teeth. This does not take into account the damage on her other teeth on the right mandible nor on the left mandible. In other words, **in 3 years, 10 months, 10 days Morgan went from 0% severe damage of her right mandibular teeth to 75%** (details of assessment are given in Appendix 3).

As discussed above, in captivity, orca dentition is a fundamental indicator of the animals compromised welfare. Damage to their teeth is an undisputable physical attribute which is extremely easy to identify, evaluate and document over time. Any layperson who viewed these teeth or photographs of them could classify each tooth according to the self-evident categories outlined in Table 1.

Yet, despite such a fundamental assessment being possible there are major irreconcilable discrepancies between the Greenwood (29 September 2015) 'Health Assessment' (two broken teeth) and the statement by Dr Almunia and the two veterinarians (22 April 2016) (no broken teeth). Interestingly, the statements by the latter three employees fall remarkably in line with the official *Loro Parque* blog (28 April 2016)<sup>21</sup> (i.e., no broken teeth). If one were to be gracious, they might consider such contradictions as nothing more than a lack of transparency. However, given that the Greenwood inspection was conducted only seven months prior to the Visser & Lisker visit, that *Loro Parque* staff have unlimited access to the animals and the trainers irrigate the damaged teeth daily, there is no logical reason for the official statement from *Loro Parque* to be so in conflict with the written and photographic evidence. The absurdity of their denial regarding Morgan's teeth is telling and casts doubt upon every assertion made by *Loro Parque* regarding Morgan in particular, but with such an alarming pattern it is also hard to consider any statements by *Loro Parque* or their employees as factual. Rather, based on the photographic evidence presented herein, the statement by Dr Almunia, the two veterinarians *and* the official blog should be totally disregarded as nonsensical.





**Figure 5.** A timeline of the self-mutilation and destruction of Morgan's teeth at *Loro Parque*. Morgan arrived at *Loro Parque* on 29 of November 2011. Her teeth had started to show apical wear upon her arrival and this escalated dramatically between June 2012 & November 2012 (top two photos – see dates embedded as yyyymmdd, in top right of each photo). Morgan has been documented as chewing on concrete since at least 2012 (see Figure 17a). Each tooth that is labeled has been damaged (see Table 1 for descriptions of damage and Appendix 2 for details of the 2016 example). Note the increase in the number of labeled teeth and also the severity of damage – including apical wear, sections breaking off and fractures. Given that this orca has been held at *Loro Parque* for less than half its life and that she arrived with her teeth in relatively robust condition, this level of damage is shocking and disturbing.

Furthermore, their inconsistencies strongly suggest that the level of competence at *Loro Parque* is well below the industry's standards and certainly below 'best practise' for health care, as well as welfare management for captive orca. This example of duplicitous behaviour is a poor reflection on the facility and calls into question whether other welfare issues, such as medical concerns are also being concealed.

Nevertheless, in the face of no other baseline to work from and despite its lack of details, the Greenwood (2015) 'Health Assessment' descriptions have been used for comparison to the photographs obtained in April 2016. If the 'Health Assessment' is a true indication of the state of each individuals' teeth at the time of his inspection it is extremely alarming to witness the acute acceleration of dental damage and stress, particularly in the two youngest orca (Adán and Morgan) (Appendix 1 & 2).

To facilitate comparisons between the 'Health Assessment' by veterinarian Greenwood on 29 September 2015 and our observations 20-22 April 2016 we have compiled a detailed appendix and summary (Appendix 1 & 2). No discussion is made by Greenwood or herein about the state of the gums of these orca although Visser (2012) notes that Morgan's gums have shown poor dental care.

The history of each orca's dental damage is not discussed, with the exception of Morgan. A tooth's damage may not be apparent from a single photograph (or even a series), in that missing tooth may have previously had moderate, then severe apical wear, been drilled, then been chipped, become fractured and then collapsed and finally been removed by staff and would now be classified as 'missing'. As Morgan has been periodically photographed since her capture, the history of her teeth is discussed.

Due to the overwhelming evidence presented herein we can only assume that; (1) the Greenwood (2015) report glossed over the dental issues and/or (2) the Greenwood (2015) report failed to identify some of the dental issues and/or (3) there is some deep-seated stress trigger for the orca at *Loro Parque* that is causing them to self-mutilate their teeth at an extremely accelerated rate. Of course these points are not mutually exclusive and there may also be other factors (*e.g.*, internal politics) contributing to the lack of accuracy when reporting or documenting welfare concerns.

The United Nations has recognised, through their Food and Agriculture Organization (FAO) legal office, the growing wealth of scientific information indicating that "*Disregard for animal welfare often leads to poor animal health*" which in turn leads to "*increased susceptibility of animal populations to disease and injury ....*" (Vapnek & Chapman 2010). That the orca at *Loro Parque* have sustained irreversible injuries to their teeth speaks volumes.

To classify the injuries that each orca has sustained through tooth damage we took the 16 categories from Table 1 and we ranked them into four groups based on the escalating acuteness of damage: Undamaged, Minimal, Moderate and Severe. The Minimal category included damage where the tooth had just started to show apical wear, or showed wear on the facet, such as a shallow groove. Additionally, any teeth which were otherwise undamaged but protruded into the gum were classified into the Minimal category as although they are likely to be causing pain to the gum there is most likely not pain to the tooth itself. The Moderate category included damage where the tooth had apical wear that was well beyond the starting point and was therefore unambiguous, but had not yet exposed the pulp spot or pulp and teeth. The Severe category included all teeth that were missing or had been broken (cracked, chipped, fractured or collapsed). It also included all drilled teeth and those where the apical wear exposed the pulp (or the 'pulp spot'). Therefore, by default this included all those teeth where the apical wear was such that they had



been nearly worn to, or to, the gum. Vestigial teeth that were exposed because of gum wear or damage were also included in the severe category, but not used in the percent calculations (see below).

Using these four groups we then ranked each tooth based on their damage (Appendix 3). Where a tooth was damaged with multiple types of injuries the most severe was applied when ranking. For example, a tooth may have moderate apical wear but also be broken (cracked). Therefore it would be ranked as having 'Severe' damage. Additionally, each tooth was only ranked once. For example, a Collapsed tooth is likely to have had 'Moderate' apical wear, then 'Severe' apical wear (*i.e.*, pulp exposed), was then 'Drilled', may have been 'Worn to gum' and with subsequent mechanical wear from chewing on hard surfaces, then 'Fractured' and finally 'Collapsed'. Such a tooth would be classified as 'Collapsed' and ranked as 'Severe'.

Where a tooth could not be ranked unambiguously, the less acute category was applied. Where a tooth was not visible or it had not been photographed, it was ranked as 'Undamaged/Unknown'. The exception was teeth which were not clearly visible due to extreme wear and their status was known due to the history of the animal (e.g., see Figure 4a-b, where Morgan's left anterior mandibular teeth are worn to the gum and Visser 2012 where her right teeth are discussed in detail and photographs presented).

Orca typically have between 11-13 teeth in each of the sides of their upper and lower jaws (Ulmer 1941, Mitchell & Baker 1980), but as we were not able to do a close inspection for smaller back teeth, we have used the median of 12 teeth per side. For example, see Figure 3a where 11 teeth are visible on Adán's left mandible, in contrast to Figure 3c where 12 teeth can be counted on the same mandible (and only 11 on his right). Vestigial teeth have not been added to the tooth count as they are typically only visible after death or due to extreme gum damage and may therefore be missed in most inspections or photographs obtained as these were, from public areas. As such, the assessments are also biased against the actual damage as an orca may have 11 erupted teeth or 11 photographed teeth, but 12 are used in the calculation. As the 12<sup>th</sup> tooth is not visible, it is also automatically designated as 'Undamaged' even though it's ranking is unknown. Assessments are, therefore, a reflection of the maximum damage on an individual *tooth*, but err on the side of minimum for the *mandible*.

Based on the escalation of tooth damage documented here, we made the assumption that teeth ranked as 'Moderate' may be up-listed to 'Severe' at any point. We have therefore combined these two categories (but excluded 'Minimal') to calculate a percentage of mandible tooth damage for each orca (Appendix 3).

It was with grave concern that we found that the minimal percentage of mandibular dental damage was 41.66% (on both Kohana and Keto). Adán, Skyla and Tekoa all had between 50% and 58.3% of their teeth ranked as Severely and Moderately damaged. Alarming, Morgan (the only wild-born orca held at *Loro Parque*) had 66.66% of her left mandible teeth ranked as Severely and Moderately damaged. Not all teeth could be completely assessed, meaning that some may rank higher than currently classified. Even more distressingly, **75% of her right mandible teeth ranked as Severely and Moderately damaged.**

Yet this is the very individual that *Loro Parque* has officially commented on, stating that; "*Morgan does not have broken teeth just abrasion in some of them.*"<sup>14</sup> To be clear, 'abrasion' is typically considered to be something superficial such as a skin scrape<sup>15</sup>, although permanent damage can occur from abrasions. An abrasion would be on the lower end of a scale of injuries, as opposed to the extreme damage we documented. This extreme damage is occurring despite claims by *Loro Parque* that there is; "... *veterinary*

<sup>14</sup> <https://web.archive.org/web/20160621171226/http://blog.loroparque.com/2016/04/?lang=en>

<sup>15</sup> <http://www.merriam-webster.com/dictionary/abrasion>

*equipment at zoos that keep orcas have a dental plan to avoid problems related to this [tooth] wear.”*<sup>16</sup> Although this quote has stilted English it attempts to convey the idea that facilities should be able to prevent the very damage that is prevalent at *Loro Parque*.

Recent published scientific research indicates that captive bears who conduct stereotypical bar biting, similar to the captive orca stereotypies of chewing on hard surfaces, are also prone to developing dental pathology. That damage can cause pain and suffering, resulting in negative welfare consequences (Fleming & Burn 2014). In the light of this and other recent welfare indicators (Section 2. WELFARE INDICATORS), the evidence presented here should not be dismissed or ignored by the industry, the welfare community or the authorities. The latter have the vital role of ensuring that minimal welfare standards are met.

In summary, the teeth of the orca at *Loro Parque* are in abysmal condition and the acute state of damage is a reflection of the systemic problems of keeping this species in captivity, particularly in concrete tanks.

---

<sup>16</sup> <https://web.archive.org/web/20160612215527/http://blog.loroparque.com/statement-lp/?lang=en>



**Figure 6a.** Skyla, female, born 09 February 2004 (i.e., 12 years, 2 months old), left side. This photograph includes the unique 'eye patch' and pigmentation inside her mouth to facilitate correct identification. Figure 6b shows close up of offending teeth.

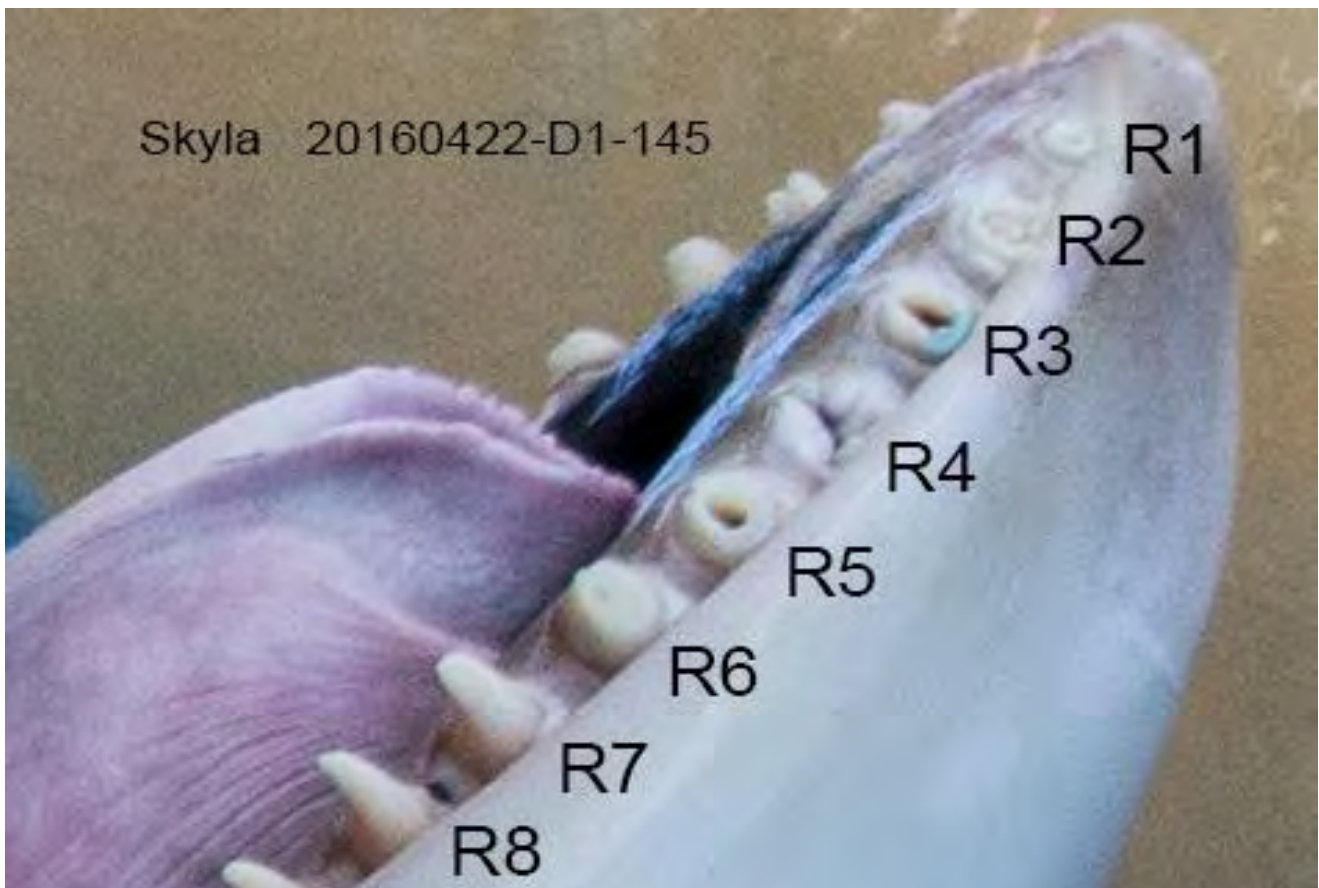

**Figure 6b.** Skyla, close up of offending teeth, left side. Note hypertrophic tissue damage (darkened zone) at the end of the mandibles. Greenwood (2015) wrote that on the 29<sup>th</sup> of September 2015 he observed Skyla and noted; *"Tooth damage included eight worn with open cavities, one missing, and one broken with secondary dentine formation."* It is unclear from this description which teeth Greenwood was referring to (maxillae or mandible, left or right), but regardless, tooth (mandible L1) is worn to the gum and has been drilled. It is not clear in this photograph if tooth (mandible L2) is broken (apex) or has moderate apical wear. Tooth (mandible L3) is broken (fractured, lingual surface missing), has been drilled and has severe apical wear. Tooth (mandible L4) shows severe apical wear with a pulp spot just beginning to show. Tooth (mandible L5) is broken (chipped, lingual surface), has severe apical wear and has been drilled. Tooth (mandible L6) broken (chipped, lingual surface), drilled, moderate apical wear. Tooth (mandible L7) apical wear is starting.





**Figure 6c.** Skyla, right side. This photograph includes the unique 'eye patch' to facilitate correct identification. Figure 6d shows close up of offending teeth.



**Figure 6d.** Skyla, close up of offending teeth, right side. Teeth (mandible R1, R2) are worn to the gum and show large holes from drilling. Tooth (mandible R3) has been drilled and is worn nearly to the gum and has blue paint on it (see tank paint scheme in Figure 15). Tooth (mandible R4) is missing. Tooth (mandible R5) has been drilled and is worn nearly to the gum. Tooth (mandible R6) has likely been drilled, is broken (chipped, lingual surface) and shows severe apical wear. Teeth (mandible R7, R8) both show the start of apical wear.



**Figure 6e.** Skyla, maxillae (upper) dentition of left side visible. This photograph includes the unique 'eye patch' and internal mouth pigmentation to facilitate correct identification. Figure 6f shows close up of offending tooth.

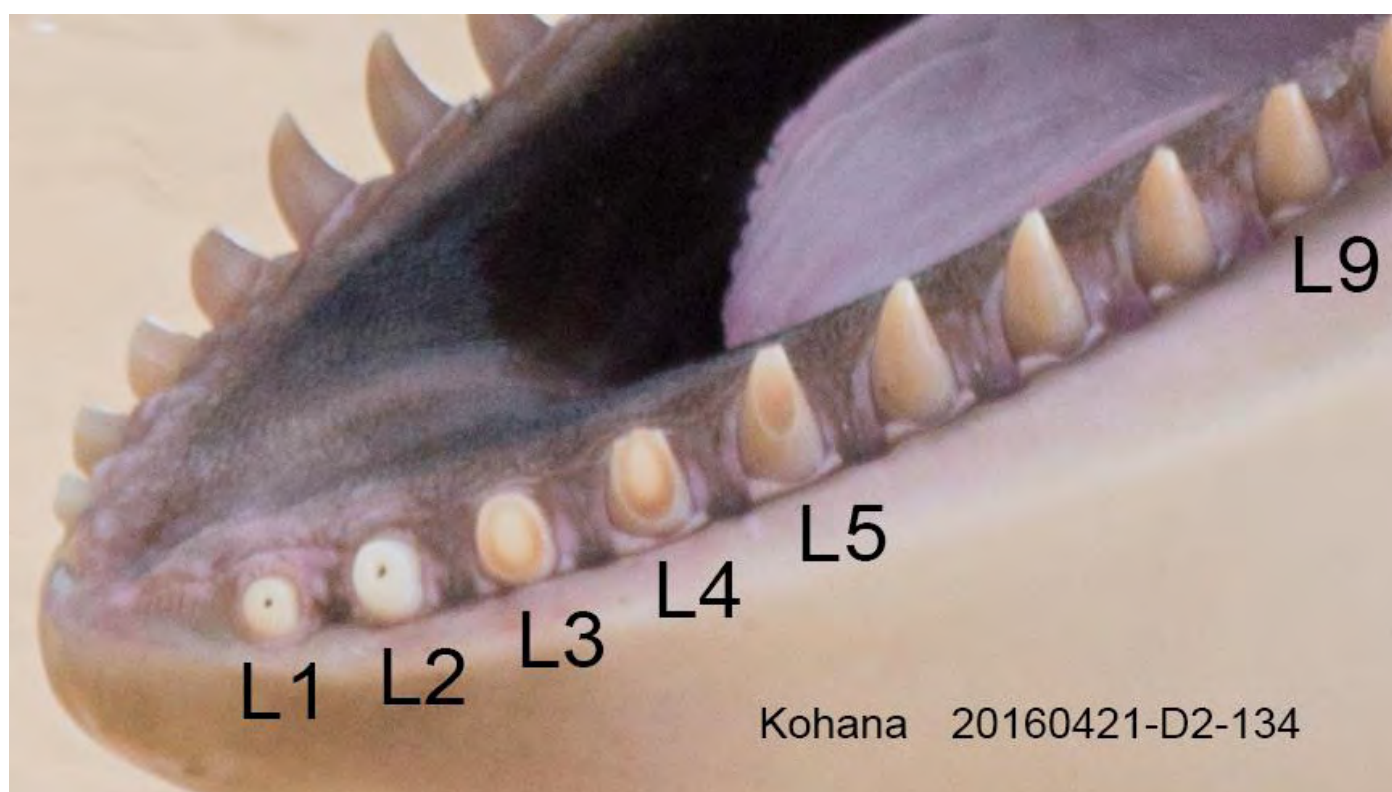


**Figure 6f.** Skyla, close up of offending tooth, left side (maxillae L2) (although it is possible this is L3 as the anterior of the mouth is not visible). This tooth protrudes into the buccal wall to the point that the inner surface of the 'lip' is malformed. The tooth is fractured (apical-basal crack, which also appears to be a separation of the enamel layer at the junction to the dentin) with severe apical wear and protrusion into the gum, with some gum overgrowth suggested. Alternatively, this tooth may be drilled and soft tissue (gum) protrudes from the apex, whilst the tooth itself protrudes into the buccal wall.





**Figure 7a.** Kohana, female, born 03 May 2002 (i.e., nearly 14 years old). This photograph includes the unique 'eye patch' to facilitate correct identification. Figure 7b shows close up of offending teeth.



**Figure 7b.** Kohana, close up of offending teeth, left side. Greenwood (2015) wrote that on the 29<sup>th</sup> of September 2015 he observed Kohana and noted; *"Most of her lower teeth at the front were worn at the side, but only five had open pulp cavities. The lower right 5th tooth had an infected socket and was under treatment."* It is unclear from this description which teeth, other than mandible R5, Greenwood was referring to (left or right). Regardless, tooth (mandible L1) is worn to the gum and has been drilled. Tooth (mandible L2) is nearly worn to the gum and has been drilled. Tooth (mandible L3) has been worn nearly to the gum. Tooth (mandible L4) is broken (chipped, lingual surface) and has apical wear nearly to the gum on the buccal surface. Tooth (mandible L5) is broken (chipped, apex) and has moderate wear. Tooth (mandible L9) has the tip either broken off or has started to show apical wear. Kohana's teeth are noticeably darker than the other orca at *Loro Parque*.



**Figure 7c.** Kohana, right side. This photograph includes the unique 'eye patch' to facilitate correct identification. Figure 7d shows close up of offending teeth.

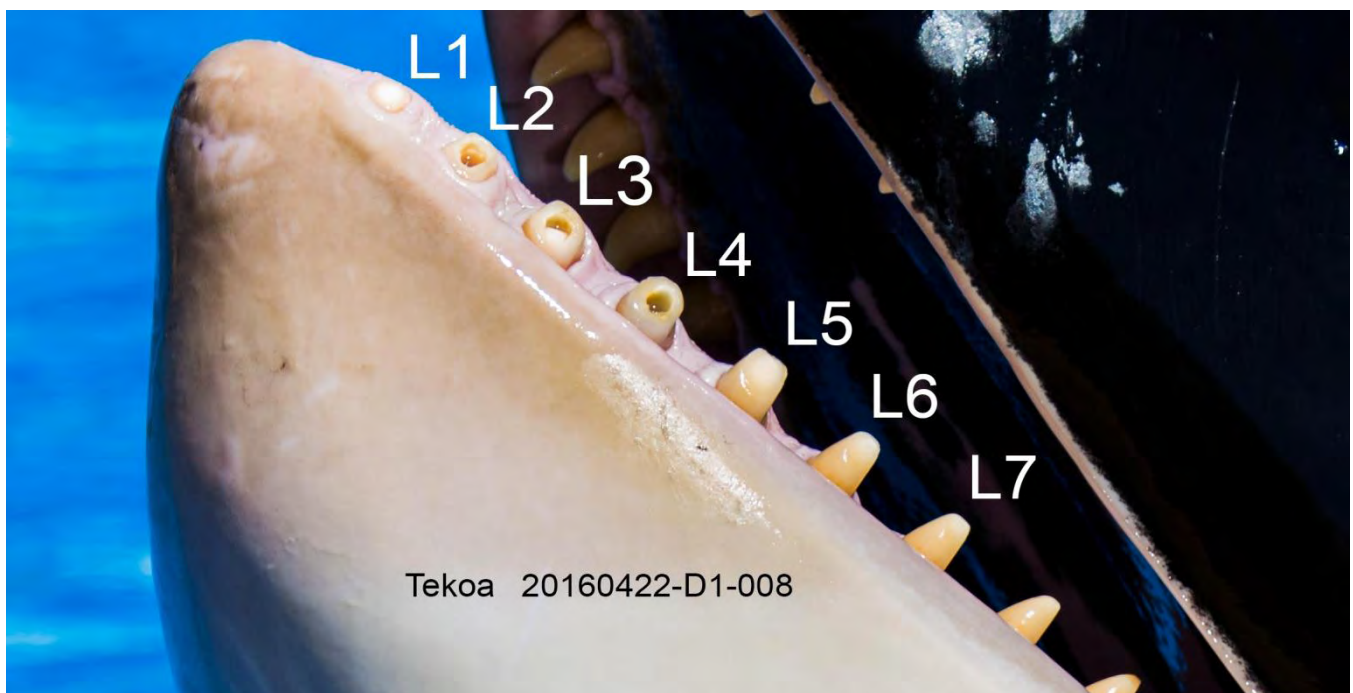


**Figure 7d.** Kohana, close up of offending teeth, right side. Tooth (mandible R1) is broken (vertical crack on buccal surface as evidenced by the dark line; see also insert (top left) for different angle, arrows indicate crack location). This same tooth has been drilled and has severe apical wear. Teeth (mandible R2, R3) have been drilled and show severe apical wear with an acute angle so the buccal surface is worn to the gum. Tooth (mandible R4) is broken (chipped, lingual surface; see insert, bottom left) and shows apical wear with an acute angle so the buccal surface is worn to the gum. Tooth (mandible R5) has moderate apical wear.





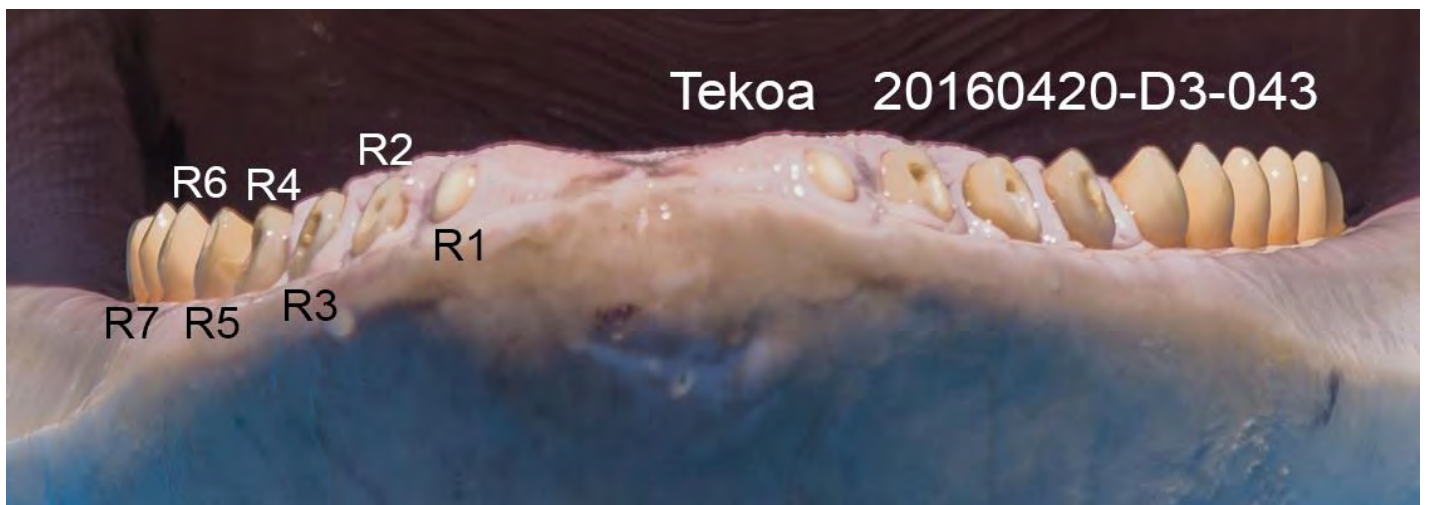**Figure 8a.** Tekoa, male, born 08 November 2000 (i.e., 15 years, 6 months old). This photograph includes the unique 'eye patch' to facilitate correct identification. Figure 8b shows close up of offending teeth.



**Figure 8b.** Tekoa, close up of offending teeth, left side. Note hypertrophic tissue damage to the end of the mandibles. Greenwood (2015) wrote that on the 29<sup>th</sup> of September 2015 he observed Tekoa and noted that he; "... showed some tooth damage, having seven worn teeth which had been drilled open, two of which had closed off the cavity with secondary dentine regrowth." It is unclear from this description which teeth Greenwood was referring to (maxillae or mandible, left or right). Regardless, tooth (mandible L1) is worn to the gum whilst tooth (mandible L2) has been drilled and is worn to the gum. Teeth (mandible L3, L4) have been drilled and show severe apical wear. Tooth (mandible L5) shows moderate apical wear and may be broken (chipped, lingual surface), while tooth (mandible L6) shows moderate wear. Tooth (mandible L7) shows the start of apical wear from chewing on the concrete.



**Figure 8c.** Tekoa, front on. This photograph includes the unique palate (upper mouth) pigmentation to facilitate correct identification. Figure 8d shows close up of offending teeth.

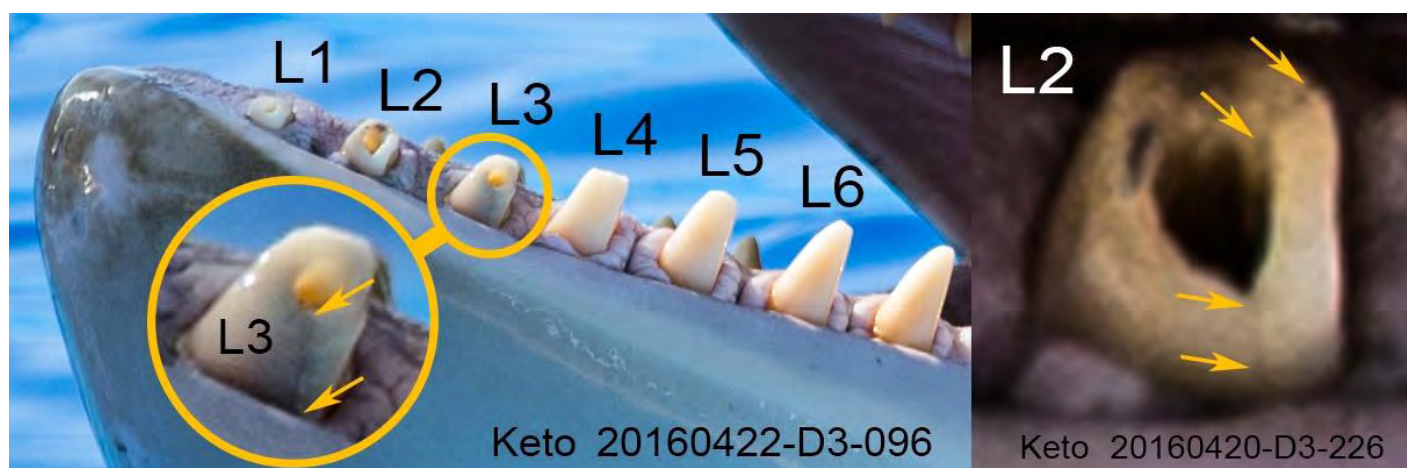

**Figure 8d.** Tekoa, close up of offending teeth. Note hypertrophic tissue damage to the end of the mandibles. The front teeth of both mandibles can be observed, however, only those of his right side are discussed here (see Figure 8b for details of left side). See text for description of orientation of this image. Tooth (mandible R1) is worn to the gum. Tooth (mandible R2) has been drilled and is worn to the gum. Tooth (mandible R3) has been drilled and nearly worn to the gum. Tooth (mandible R4) tooth appears to be broken (chipped, distal surface), it has been drilled and has severe apical wear. Tooth (mandible R5) has been drilled and has severe apical wear. Teeth (mandible R6, R7) show apical wear from chewing on the concrete, but it is not possible to ascertain if they have the pulp exposed (severe wear) and are therefore classified here as having moderate wear.






**Figure 9a.** Keto, male, born 17 June 1995 (i.e., 20 years, 10 months old). This photograph includes the unique 'eye patch' to facilitate correct identification. Figure 9b shows close up of offending teeth.

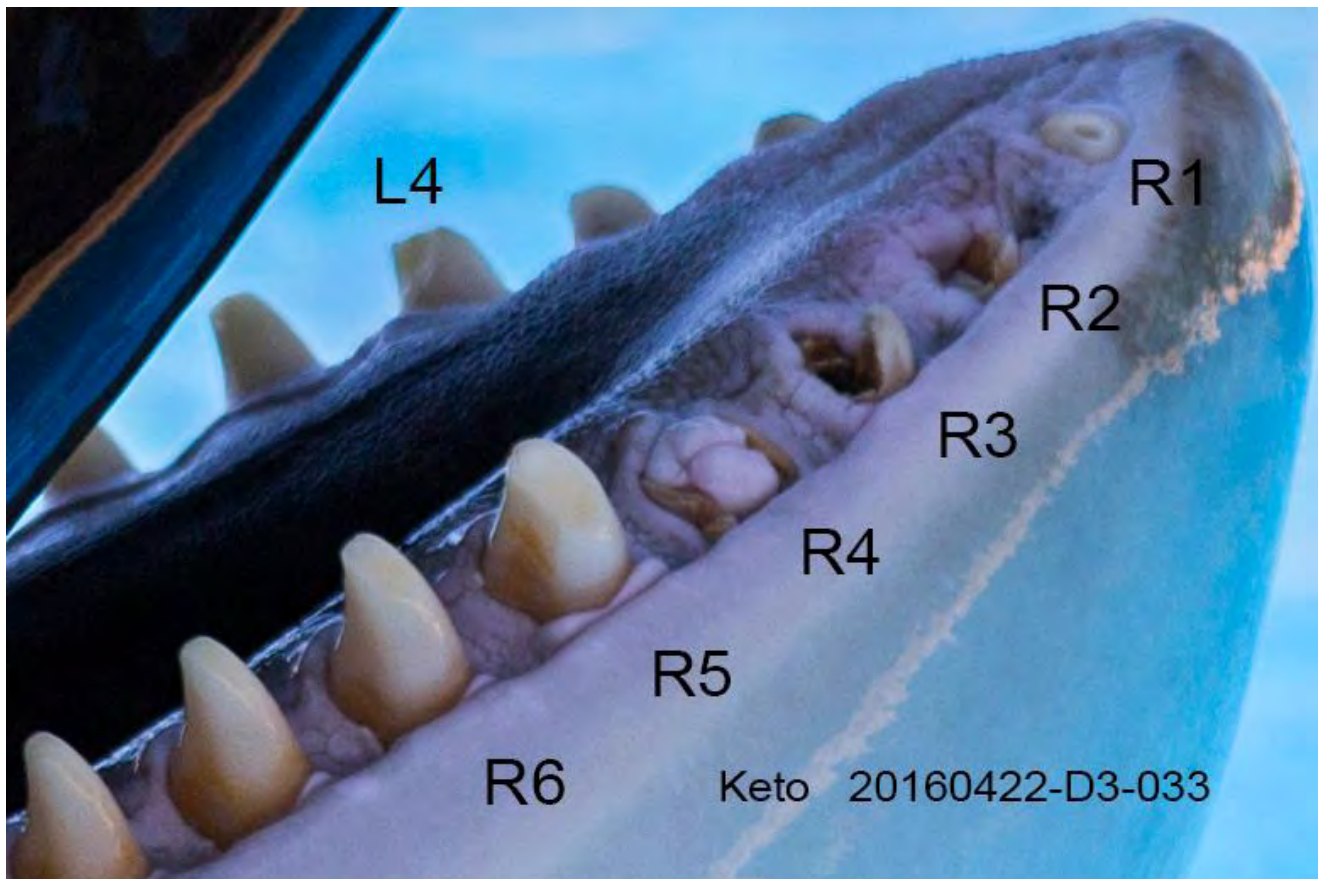

**Figure 9b.** Keto, close up of offending teeth, left side. Note hypertrophic tissue damage to the end of the mandibles. Greenwood (2015) wrote that on the 29<sup>th</sup> of September 2015 he observed Keto who “ ... showed some tooth damage which was under continuing treatment. Seven lower front teeth were worn and their dead pulp cavities had been drilled out and widened to allow regular flushing to prevent infection. Two such teeth had collapsed and small pieces had fallen out or been removed. Keto was also missing four upper teeth on his left side (which had occurred more than ten years ago before arrival at Loro Parque).” It is unclear from this description which teeth Greenwood was referring to (left or right). However, tooth (mandible L1) has been drilled and is nearly worn to the gum. Tooth (mandible L2) is broken (vertical crack on buccal and lingual distal surfaces; see insert (right) which has the contrast and levels adjusted so the cracks are visible, arrows indicate crack locations) has been drilled and is nearly worn to the gum. Tooth (mandible L3) is broken (a vertical crack on the buccal edge and a possible vertical crack on the anterior lingual edge, see enlargement with arrows, circled), has been drilled and has severe apical wear. It also appears to be chipped on the distal surface at the apex. Tooth (mandible L4) is broken (chipped, lingual and mesial surfaces; see Figure 9d for another angle of this tooth) and shows severe apical wear, whilst tooth (mandible L5) is broken (chipped, lingual surface) and shows moderate apical wear apparently from chewing on the concrete. Tooth (mandible L6) is starting to show apical wear.





**Figure 9c.** Keto, right side. This photograph includes the unique 'eye patch' to facilitate correct identification. Figure 9d shows close up of offending teeth.



**Figure 9d.** Keto, close up of offending teeth, right side. Note hypertrophic tissue damage to the end of the mandibles. Tooth (mandible R1) has been drilled and is worn to the gum. Teeth (mandible R2 & R3) are broken (fractured into pieces and collapsed) and have been drilled. Small sections of these teeth still remain vertical and protrude just above the gum, otherwise the rest of the tooth is worn to the gum. Tooth (mandible R4) has been drilled and is worn to the gum, which protrudes into and over the tooth. Tooth (mandible R5) shows moderate apical wear and tooth (mandible R6) has started to show apical wear, apparently from chewing on the concrete. Tooth (mandible L4) is also labelled here to show another angle as it has a broken (chipped lingual/distal surface) and possibly chipped mesial edge (see Figure 9b).



**Figure 9e.** Greenwood noted “Keto was also missing four upper teeth on his left side (which had occurred more than ten years ago before arrival at Loro Parque).” These are identified here as likely to be (maxillae L4, L5, L6, L7). No explanation was given by Greenwood as to why these teeth were missing. Keto can be identified in this photograph by matching the drilled teeth in his mandible to those in Figures 9c & 9d.

## 2. WELFARE INDICATORS

In 2012, a report by Visser focused on ‘Morgan’ and the issues surrounding her captivity at *Loro Parque*. Since the release of that report, a range of information, evidence and accounts have continued to be gathered by the FMF. Many concerned citizens, who come from a range of countries, have contacted the FMF and they have repeatedly raised welfare concerns for the orca held at *Loro Parque*, including Morgan. The FMF has conducted a number of visits to the facility and repeatedly observed the same issues.

The information gathered by the FMF and presented here, illustrate that the issues described in the Visser (2012) report continue and that these issues are therefore of increasing concern given their duration, *i.e.*, in the magnitude of years. The welfare indicators that the FMF has used in the past (and herein) to signify compromised welfare include *inter alia*; aggression, bite and rake marks, stereotypies (abnormal, repetitive behaviours), confinement, self-mutilation, physical attributes (such as weight, eyes, dentition) and health (such as immune related issues, pathogens, etc.). Furthermore, the general behavior, within the framework and in the context of wild orca behavior, has been documented by the FMF and members of the public at *Loro Parque*. This is of particular consequence when discussing Morgan who is wild-born and the behaviours she has been documented conducting whilst at *Loro Parque*.



On 4 May 2016, a workshop investigating potential welfare indicators for captive marine mammals and hosted by the Nuremberg Zoo, the European Association of Zoos and Aquaria, the Alliance of Marine Mammal Parks and Aquariums, the World Association of Zoos and Aquariums and the European Association for Aquatic Mammals (EAAM)<sup>17</sup>, was held in Nuremberg, Germany. The EAAM is a professional voluntary membership-based organisation for zoological parks, aquariums and individuals interested in the conservation and welfare of aquatic mammals. The workshop was opened to non-members. The authors of this report (Visser & Lisker, both board members of the FMF) applied and were accepted as delegates. At the workshop Dr Visser participated as an expert in a Q&A session. That panel also included Dr Almunia from *Loro Parque*.

It is significant to note that the evidence presented herein was gathered prior to and independent of the welfare workshop. However, the points discussed below are all indicators that were stressed and highlighted at the workshop as indicative of compromised welfare for captive cetaceans.

Additionally, it is important to keep in mind the 'Five Freedoms' of animal welfare. Not only are these industry-wide standards internationally recognised as providing the *minimal requirement* for an animal's physical and mental well-being (Botreau *et al.* 2007), but the Five Freedoms are also recognised by the United Nations, the World Organisation for Animal Health (OIE) and the Terrestrial Animal Health Code 2010. They have been updated into the 'Five Domains' (Mellor & Stafford 2001) which has been the platform for the 'Positive Welfare States' (Mellor 2015a, Mellor 2015b, Mellor 2015c).

*Loro Parque* themselves purport to adhere to the basic Five Freedoms as evidenced by a sign at the entrance to the orca show stadium (Figure 10). Their interpretation has been modified from the Five Freedoms and they call these standards 'principles'. The English section reads: "*The five principles When training our animales, [sic] we adhere strictly to the five principles of animal welfare: - Freedom from hunger and thirst – Freedom from thermal and physical discomfort – Freedom from pain – Freedom to express normal behaviour – Freedom from fear and distress*". Their modification, tellingly excludes 'Freedom from injury and disease'.

Botreau *et al.*, (2007) developed criteria for overall assessment of animal welfare that can be applied across species. They consulted an advisory committee of representatives of consumers, distributors, producers, animal advocates and policy makers who were all in agreement with their four criteria and 12 sub-criteria. In addition, discussions were organised in 49 focus groups of consumers (in seven European countries) and these showed that consumers considered their list as a relevant basis to assess welfare.

Disturbingly, despite more than 50 years of holding orca in captivity, there is a complete vacuum of any peer-reviewed papers regarding their welfare or assessment of welfare, something that the industry clearly has a responsibility to produce. The only peer-reviewed cetacean welfare-specific assessment was published as recently as just last year (Clegg *et al.* 2015). In that paper the authors have compiled an assessment for the welfare of captive bottlenose dolphin welfare based on the Botreau *et al.* (2007) criteria, which they then adapted for the aquatic environment and dolphins in particular. The criteria used were based on "*evidenced potential for application to other species in managed care*". Therefore, all the criteria used to assess bottlenose dolphins are applicable to orca. Orca are the largest member of the Delphinidae family and therefore directly comparable welfare-wise to bottlenose dolphins.

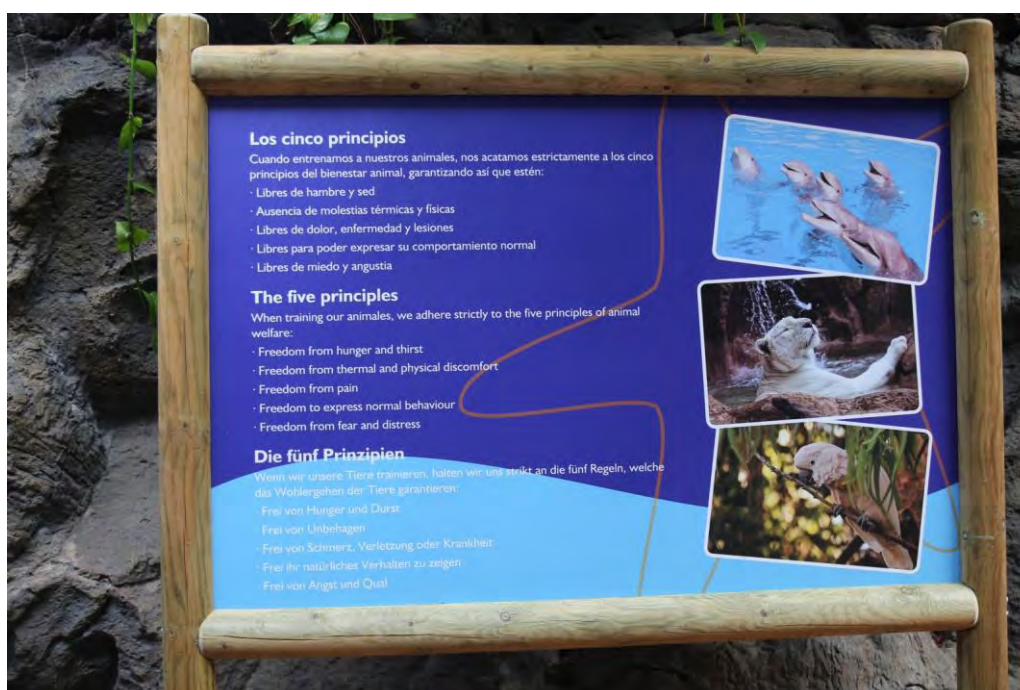In order to facilitate ease of access of the Clegg *et al.* (2015) criteria, they are reproduced in Appendix 4.

<sup>17</sup> <https://web.archive.org/web/20160612215838/http://www.eaam.org/open-announcements/animal-welfare-workshop/>



Regardless of which animal welfare standards are used, *Loro Parque* frequently prevents orca from expressing both natural body postures and normal behaviour. Common sense dictates that any violation of such a basic minimum standard is also a general welfare issue.

Unfortunately, during Visser & Lisker's visit to *Loro Parque* this was not the only violation of the Five Freedoms that we observed. Violations of the cetacean-specific C-Well® welfare standards were also obvious. In fact, at least four violations of the Five Freedoms and **23 violations** of the cetacean-specific welfare 'measurements' described by Clegg et al. (2015) were documented. Violations are not mutually exclusive and take into account that a single indicator may represent more than one 'Criterion', or 'measurement' of violation (e.g., the symptom of squinting – listed as an indicator (measure) under the C-Well® criteria 'Absence of disease; (eye diseases, squinting)', may be a result of a violation of (a) lack of shade, (b) reaction to poor water quality (chemical/pH etc.) or (c) a sign of a pathogen/infection. A summary of breaches by *Loro Parque*, which were documented by Visser & Lisker are outlined in Table 2.



## The five principles

When training our animales, we adhere strictly to the five principles of animal welfare:

- Freedom from hunger and thirst
- Freedom from thermal and physical discomfort
- Freedom from pain
- Freedom to express normal behaviour
- Freedom from fear and distress

**Figure 10.** A sign at the entrance to the orca show stadium (top) at *Loro Parque* with an enlargement (bottom). This sign has been present at the park since at least 17 November 2013 and was photographed during our April 2016 visit. It lists the Five Freedoms ('Five Principles'). The fourth and fifth on the list; "Freedom to express normal behaviour" and "Freedom from fear and distress" are violated when an orca is placed in the medical tank. If an orca hurts itself whilst anywhere in an enclosure, the third on the list "Freedom from pain" is also violated (see text and Table 2 for more details and other violations).

**Table 2.** Summary of breaches of minimal animal welfare standards, by *Loro Parque*. These are specifically with respect to orca. Violations are not mutually exclusive. See text for details.

Description	Violation? (if yes, explanation)	Description	Violation? (if yes, explanation)
<b>5 Freedoms</b>		<b>C-Well®</b> (Clegg et al., 2015)	
Freedom from hunger & thirst	Unknown <sup>1, 2</sup>	1 Absence of prolonged hunger	Unknown <sup>1</sup>
		2 Absence of prolonged thirst	Unknown <sup>2</sup>
Freedom from thermal and physical discomfort	<b>YES.</b> (1) no shade; (2) confinement in tank too small to exhibit normal body posture; (3) dental procedures performed (drilling, irrigation)	3 Resting comfort 3.1 time budget 4 Thermal comfort 4.1 shade 5 Appropriate environment 5.1 topography 5.1.2 complexity 5.2 complex movements 5.2.1 swim speed 5.2.2 aerials 5.3 Water quality 5.4 Enrichment 5.4.1. application of	<b>YES.</b> (3.1) excessive logging (not swimming) (4.1) In medical tank no shade; (5.1 & 5.1.2) inappropriate environment as no topography & no complexity; (5.2) in medical tank no ability to exhibit complex movements; (5.2.1) in medical tank no swim speed, in other tanks significantly reduced; (5.2.2) in medical tank no aerials; (4.1, 5.3) eye mucous discharge likely symptom eye stress (sun/chemicals/water quality); (5.4.1) minimal application of enrichment;
Freedom from pain	<b>YES.</b> (1) dental procedures performed (drilling, irrigation); (2) excessive aggression from other orca; (3) wounds from enclosure (dental damage & self-mutilation)	6 Absence of injuries 6.1 total wound threshold 6.2 wounds from enclosure  7 Absence of disease 7.2 eye diseases 7.2.2 squinting 7.3 skin diseases 7.3.1 skin abnormalities 7.3.2 mouth abnormalities  8 Absence of pain induced by management procedures 8.4 Emergency containment training	<b>YES.</b> (6.1) total wound (from aggression), (6.2) wounds from enclosure (dental & self-harming stereotypies)  <b>YES.</b> (7) Candidiasis (fungal infection) (7.2) eye mucous discharge likely symptom eye stress (sun/chemicals) (7.2.2) squinting documented (7.3.1) skin abnormalities (wrinkles, pocks, unidentified cream, abrasive/scuff marks) (7.3.2) mouth abnormalities – dental damage, gingivitis, hypertrophic tissue damage to mandibles  <b>YES.</b> (8) dental procedures (drilling, daily irrigation) (8) self-harming stereotypies due to confinement (8.4) Emergency containment training (medical tank)
Freedom to express normal behaviour	<b>YES.</b> normal behaviours prevented (1) at all time, but extreme when locked in medical tank; (2) due to inappropriate social grouping	9 Expression of social behaviours 9.1 Presence of social behaviours  10 Absence of abnormal behaviours (Stereotypic)	<b>YES.</b> (9, 9.1) inappropriate social grouping (dysfunctional group, no matriarch, hybrids, wild-born with captive-born, inbreeding) (9.1) abnormal social behaviour prevalent (e.g., excessive aggression, inbreeding),  <b>YES.</b> (10) stereotypies prevalent & excessive on all individuals, self-mutilation documented on all individuals
Freedom from fear and distress	<b>YES.</b> (1) when locked in medical tank; (2) inappropriate social grouping (aggression)	11 Positive human-animal relationship	<b>YES.</b> (11) Multiple incidents of attacks on trainers, including a fatality <sup>3</sup> (11) Relationship completely distorted by trainer-food coupling & 'optimum working weight' <sup>1,2</sup>
<b>MINIMUM # of VIOLATIONS</b>	<b>4</b>	<b>MINIMUM # of VIOLATIONS</b>	<b>23</b>

<sup>1</sup> Orca in captivity are kept at what is termed 'optimum working weight' – i.e., the amount of food provided each day is tightly controlled and limited (Hargrove & Chua-Eoan 2015). They are fed approximately 2–3% of their body weight per day- as cited by SeaWorld in Robeck et al. (2004). Food is typically kept at a level to promote maximum adherence to commands throughout the day, as an orca that is satiated is less likely to respond to orders.

<sup>2</sup> Orca in the wild receive all their water requirements from their food. In captivity the quality of the fish is compromised (due to being frozen) and therefore water intake must be continually supplemented.

<sup>3</sup> <https://web.archive.org/web/20160712061516/http://www.outsideonline.com/1886916/blood-water>

### 3. INAPPROPRIATE USE OF THE MEDICAL TANK & LACK OF SHADE

Facilities holding orca typically have one tank that is substantially smaller and shallower than the other tanks. This tank is typically termed the ‘Medical Tank/Medical Pool’ and may or may not have a floor that can be mechanically raised. These confined spaces and lifting floors provide access to the animals when medical procedures are required. Unfortunately, they are also inappropriately used for segregation and / or as holding tanks.

Since Morgan’s arrival in 2011, it has been brought to the attention of the FMF that *Loro Parque* repeatedly and incongruously uses their medical tank (Figures 11a & 11b) as a holding tank. On their official blog they state that “... the orcas are trained daily to enter and remain quiet within medical pools ...”<sup>18</sup>. Although Visser & Lisker recognise that ‘desensitisation training’ of the orca may be required to ensure safe use of a medical tank, this type of delicate conditioning is necessary only because orca become stressed due to the extremely confining conditions of such a tank and the potential of raising the floor. Therefore, with the exception of short desensitisation sessions, medical tanks should only be used for medical events as they are absolutely unsuitable for persistent use as holding tanks.

The medical tank dimensions are given by *Loro Parque*<sup>19</sup> as; depth 4.2m (13.8ft), width 7.1m (23.3ft) and length 12.4m (40.7ft) (Table 3). However, note that these measurements are not clear as to the inclusion or exclusion of the ledge along the full length of the northern side of the tank. This ledge is typically at, or just below the water level (see ledge to the north in Figure 11a and to the right of frame in Figure 12a-b). This ledge is estimated at approximately 1m (3.3ft) wide and if included as part of the calculations, then the actual width that the animals have to use within the medical tank is potentially only 6.1m (20ft).

Additionally, it should be noted that the floor of the medical tank at *Loro Parque* can be varied at will to any depth ranging from a maximum of 4.2m (13.8ft) to zero water (see Figure 12a-b & Figure 13), therefore the actual depth of the tank at any one time can never be guaranteed. Consequently, the actual dimension of the depth – and thereby also the cubic dimension for the medical tank as a whole – cannot be verified. As such, there is no way to ensure that the maximum depth is maintained while any orca are held in the medical tank. Furthermore, there are no assurances that the tank floor is returned to its maximum depth as quickly as possible following a medical event or a desensitisation session. At times when the floor is raised, even if water remains, the orca cannot swim (Figure 13).

Furthermore, at unknown intervals, (and apparently for extended periods lasting weeks) maintenance is undertaken. For example, *Loro Parque* placed signs near the ‘Orca Ocean Stadium’ informing the public they were conducting maintenance during the period 04 April-21 May 2016 (*i.e.*, six weeks, see Figure 14). During the visit by Visser & Lisker, the west holding tank, which adjoins the medical tank, was drained of water (see Figure 15). For at least three days (20-22 April), the water level in the remaining three tanks (*i.e.*, show tank, east tank and the medical tank) was lowered by approximately 0.5m (1.6ft). Therefore, the water depth in the already extremely shallow medical tank, was a maximum of 3.6m (11.8ft).

Using a medical tank for holding orca is incompatible with, and in direct conflict of the animals’ welfare, *i.e.*, it prevents an orca from the freedom to express both fundamental natural body postures and normal behaviour. Such a violation is an unequivocal contravention of the most basic animal welfare standards;

<sup>18</sup> <https://web.archive.org/web/20160705011215/http://blog.loroparque.com/enough-of-false-accusations-against-loro-parque/?lang=en>  
<sup>19</sup> Page 15 in <http://www.freemorgan.org/wp-content/uploads/2012/10/Almunia-2012-report-on-the-introduction-of-a-rescued-orca-into-Loro-Parque.pdf>



the ‘Five Freedoms’ and the cetacean-specific C-Well® criteria. Furthermore, common sense dictates that holding multiple orca in a medical tank only increases welfare concerns.

As background information, it is worth noting that one of the main reasons given to the Dutch High Court, by *Dolfinarium Harderwijk*, for transferring Morgan to *Loro Parque* was that their holding tank in the Netherlands was grossly inadequate in size and as such Morgan’s welfare was severely compromised. The tank was so cramped she was unable to hang vertically or exhibit other natural body postures and she was unable to conduct normal behaviour (see Figure 19, page 22 in Visser & Hardie 2011). The dimensions of the tank at *Dolfinarium Harderwijk* were; length 21m (68.9ft), width 7.5m (24.6ft) and depth 2.8m (9.2ft) (Neves dos Reis 2014). Morgan was (as of June 2011): 3.65 m (11.9ft). This equated to a holding tank that was shallower than she was long.

A comparison between the *Dolfinarium Harderwijk* tank, the *Loro Parque* medical tank and Morgan’s size is given in Table 3. From there it can be seen that effectively the medical tank, given Morgan’s current body size, is proportionally smaller than the tank she was moved out of. To put the calculations into perspective, as of 28 April 2016 Morgan’s length is reported as 5.1m (16.7ft)<sup>20</sup> and her weight in excess of 2,200kg (4,850lb)<sup>21</sup>. Adult female orca can reach lengths of 8.5m and 7,500kg (16,535lb) in weight (Jefferson *et al.* 2008). Therefore if *Loro Parque* continues to inappropriately use their medical tank, the suffering will only increase for Morgan as she grows larger.

**Table 3.** Comparison of tank size at *Dolfinarium Harderwijk* to the medical tank at *Loro Parque* and Morgan’s size. The measurements under ‘Morgan’s length *cf* Dimension’ are a ratio of how many body lengths (of Morgan at that particular size) would be accommodated by that tank’s dimensions and the percentage of her body length compared to the tank dimension. For example, a ratio of 2 would equal two body lengths, which is 50% of the tank dimension. It is apparent given Morgan’s growth that the medical tank at *Loro Parque* is comparatively much smaller than the tank at *Dolfinarium Harderwijk*, yet one of the primary reasons Morgan was moved was due to small tank size.

Tank Dimensions	<i>Dolfinarium Harderwijk</i>	Morgan’s length <i>cf</i> Dimension	<i>Loro Parque</i>	Morgan’s length <i>cf</i> Dimension
Length	21m (68.9ft)	x5.6 / 17.4%	12.40m (40.7ft)	x2.4 / 41.1%
Width	7.5m (24.6ft)	x2.1 / 48.7%	7.10m (23.3ft) <sup>B</sup> [6.10m (20ft)] <sup>B</sup>	x1.4 / 71.8% [x1.2 / 83.6 %]
Depth	2.8m (9.2ft)	x0.8 / 130%	4.20m (13.8ft) <sup>C</sup>	x0.8 / 121%
Morgan’s length	3.65m (11.9ft) <sup>A</sup>		5.10m (16.7ft) <sup>D</sup>	

<sup>A</sup> as of June 2011, five months prior to transfer to *Loro Parque*

<sup>B</sup> May be 1m less taking into account ledge

<sup>C</sup> Maximum depth as the floor can be raised to zero water (see Figures 12a-b and 13)

<sup>D</sup> as of 28 April 2016

<sup>20</sup> Pers. comm. Dr Javier Almunia, Loro Parque Foundation, email correspondence to Visser, dated 20160428.

<sup>21</sup> <https://web.archive.org/web/20160705011215/http://blog.loroparque.com/enough-of-false-accusations-against-loro-parque/?lang=en>

It is worth considering that the maximum depth of the medical tank at *Loro Parque* is 1m (3.3ft) **less** than her current length. The maximum width of the medical tank gives Morgan only 2m available space beyond her own length (see Figures 4a-b & 12a-b). The maximum length of the medical tank is only x2.4 of her body. Once she is locked in the tank it is vital to remember that one body length is already occupied by Morgan, so when calculations are made of 'how many body lengths' are available to her, there is effectively one less than indicated. For example, if a tank was 10.2m long it would therefore be exactly x2 Morgan's body length, but she would actually only be able to swim forward one body length. Unfortunately, it seems that it must be continually reiterated that using the medical tank for anything other than desensitisation, medical and husbandry is totally unacceptable and inhumane.

Subsequent to her transfer to *Loro Parque* on 29 November 2011, observations were made at *Loro Parque* from June 2012 onwards, for submission to the Dutch High Court (Raad van State) as part of an administrative appeal regarding the transfer of Morgan. From that 2013 data, it was noted that Morgan was used in the commercially driven and circus-like shows and that she was kept locked in the medical tank more than 70% of the observed time (unpublished data, presented to the Netherlands Court). While Morgan was locked in the medical tank no veterinarian attended her, no medical tests were performed and trainers had minimal contact with her. Furthermore, no environmental enrichment was provided to Morgan whilst she was locked in the medical tank. During 20-22 April 2016, Visser & Lisker observed nine shows (three shows per day). Their documentation illustrated that the pattern of holding Morgan in the medical tank remains similar. During seven of the shows (77%) Morgan was again confined in the medical tank. No veterinarian attended Morgan, no medical tests were performed and the trainers had minimal contact with her. Furthermore, no environmental enrichment was provided to Morgan whilst she was locked in the medical tank. She was also, again, used in the commercially driven circus-like shows.

Whilst locked in the medical tank Visser & Lisker have observed Morgan floating in an apparent catatonic state, not responding to her surroundings, as well as chewing repeatedly on the concrete walls of the tank. Morgan also shows more graphic types of behavioural responses (thrashing, stereotypies) when locked in the medical tank. All these reactions are confinement-specific indicators that welfare is compromised.

To illustrate the distress that detention in such a small area can create, there is dramatic online video of Morgan stridently calling out, thrashing around and banging her head<sup>22</sup>. She rams the eastern segregation gate hard enough to create violent and clearly audible bangs. The medical tank segregation gates (one each at the west and east ends, see Figure 11b) are solidly constructed with heavy pipe-metal (Figure 16). Based on the known dimensions of the medical tank, they are more than 4m (13ft) high and approximately 3m (9.8ft) wide (see the painters in Figure 15 for scale). As such, it would require great force for either to be moved so violently that a 'bang' can be recorded on an (amateur) video camera from at least 35m (115ft) away, especially when the gate is also moved through the dense medium of water. Such fierce ramming may result in self-harming injuries such as fractured teeth as reported by Ventre & Jett (2015). If such harm occurs, then this would be a violation of yet another of the Five Freedoms ("Freedom from pain, injury and disease") and a violation of another two of the Clegg et al. (2015) Welfare Criteria and their related measurements ("Absence of injuries, Wounds from enclosure" and "Absence of pain induced by management procedures").

<sup>22</sup> <https://web.archive.org/http://www.dailymail.co.uk/news/article-3562502/Shocking-footage-shows-captive-SeaWorld-killer-whale-repeatedly-banging-head-distress-Tenerife-park-orca-trainer-attacked-killed.html>

These vivid actions of Morgan clearly indicate acute elevated levels of distress. *Loro Parque* has admitted, again on their official blog, to locking Morgan into the medical tank on this day. However, they regrettably seem unable to recognise, or admit, that this behaviour is not acceptable and have rather stated that it was “... a completely normal situation in which there is no problem for the animals.”<sup>19</sup> Such comments clearly illustrate that their baseline to interpret such behaviours is one that is already severely compromised. It therefore only provides a warped perception of what is ‘normal’. Unfortunately, without experience of observing wild orca behaviour such claims by the industry are automatically distorted and *Loro Parque’s* own statement illustrates this when they also write “*The interpretation of a panic attack is completely ridiculous, given that the orcas are trained daily to enter and remain quiet within medical pools*”<sup>23</sup>. [emphasis added]. They somehow fail to see that Morgan is doing anything but remaining quiet. Furthermore, anyone with even the most basic understanding of animal behaviour can recognise that the thrashing, strident calling and smashing into the gates is far from ‘normal’, ‘natural’ or even a ‘trained’ behaviour. Keeping Morgan locked in the medical tank when she shows substantial anguish and stress is another violation of one of the Five Freedoms, in this case the right to “Freedom from fear and distress”.

During observations made 20-22 April 2016, the authors found that for more than half the time that Morgan was locked in the medical tank, she was kept in there with the male orca Tekoa. In April 2016, Tekoa was 15 years & 6 months old (he was born in captivity at *SeaWorld* Orlando, USA, 08 November 2000) and as such, due to age and sexual dimorphism of the species (not only length and appendages, but also weight – he currently weighs 500kg (1102lb) more than Morgan<sup>19</sup>), he is physically much larger than Morgan. On 22 April 2016, Visser & Lisker observed and photographed **three** orca (Morgan, Tekoa and Adán) all locked together in the medical tank during a show (Figure 17). Logically, there is reduced retreat space with three animals in there together and confinement in such a tiny tank, regardless of the size differences (and in these cases exacerbated by it), places additional physical and social stressors on all of the orca. At no point were the orca (in any social combination) provided any environmental enrichment, nor did any veterinarian attend, no medical tests were performed and trainers had minimal contact with the three orca for the duration of the time they were locked in there together.

It has been recognised for decades that relentless exposure to persistent stressors such as undue confinement can have many deleterious consequences that are particularly undesirable for animals maintained in captivity (Morgan & Tromborg 2007). It has also been shown in bottlenose dolphins (the only cetacean species this particular type of study has been conducted on), that dolphins kept in open (seapen style) facilities spent significantly less time floating and swimming in circular patterns than linear ones, compared with dolphins in closed (concrete tank) facilities. This may be to increased complexity of ‘open’ facilities, compared to barren concrete tanks. Dolphins kept in open facilities also had significantly lower salivary cortisol concentrations (an indicator of stress levels) than dolphins kept in closed facilities.

Furthermore, when assessing bottlenose dolphin welfare (currently, again, the only welfare specific assessment paper has been done on cetaceans), Clegg et al (2015), list in their Table 1 a range of ‘criterion’ & ‘measures’ to consider for good welfare. This includes *inter alia*; (1) Ability to exhibit complex movements, (2) swim speed (3) aeriels, none of which can be achieved by any orca held in the medical tank, *i.e.*, all these welfare criteria would be violated. Additionally, they list “Application of enrichment” as a measure under ‘Appropriate environment’ (#5.4.1 in their Table 1) and again this was violated by *Loro Parque*, as at no point was any environmental enrichment provided to the orca locked in the medical tank.

<sup>23</sup> <https://web.archive.org/web/20160705011215/http://blog.loroparque.com/enough-of-false-accusations-against-loro-parque/?lang=en>



The walls of the medical tank (along with the walls & floors of the other tanks at *Loro Parque*) are painted light blue (Figure 15), apparently to either make the orca readily visible for visitors and/or to give the impression that the tank is not just a concrete box, but rather a more natural environment such as the 'ocean' (note that *Loro Parque* has named the stadium and its associated tanks 'Orca Ocean').

The medical tank floor (which can be raised) is an even paler colour than the tank walls (see Figure 12a-b). Such pale colours increase light reflectance and expose the orca, including their sensitive eyes, to higher levels of UV radiation, especially in a tank that is only 4.2m (13.8ft) deep. It has been noted in the scientific literature that the natural mechanisms used by cetaceans to minimize UV radiation exposure (*i.e.*, spending most of the time submerged in deep water or if in shallow water in habitats with non-reflective substrates) are unavailable to those held in captivity (Couquiaud 2005).

Furthermore, with *Loro Parque* being located at 28°24' north, the average daily sunshine in June, July and August is nine hours. The lowest daily average of daily sunshine is in December, with five hours. The hottest month is August with an average temperature of 24°C (75°F) and the coldest being January 17°C (62°F)<sup>24</sup>. With such intense exposure, shade must be provided for the orca over the extremely shallow medical tank particularly with its highly reflective floor. Clegg et al (2015), when looking at the welfare of bottlenose dolphins in captivity used 'shade' as one of the indicators to assess 'good housing'.


During Visser & Liskers' observations globules of mucus could be seen below Morgan's eyes (Figure 18). Concerns about mucus being expelled from Morgan's eyes have been raised previously (*e.g.*, to the Netherlands court<sup>25</sup>). Additionally, at times the orca, particularly when lifting their heads above the water level, had their eyes closed (Figure 19). During decades of observing orca in the wild, Visser (unpublished data) has never recorded orca that, when lifting their heads out of the water, close their eyes, unless they were oriented towards the sun. The scientific literature has recognised for decades now, that spyhopping (the behaviour of cetaceans to lift their heads out of the water, typically up to or beyond their eyes) is a way for the animals to observe the environment above the water level (*e.g.*, see Jacobsen 1986, Yano & Dahlheim 1995 as just two examples pertaining to orca specifically.). It can only be speculated as to why the orca at *Loro Parque* should frequently have their eyes closed but the lack of shade must certainly be considered, as must the chemical additives which are used to treat the water at *Loro Parque*.

Cetaceans are also known to be susceptible to sunburn (Martinez-Levasseur *et al.* 2011). The use of black zinc oxide cream to help prevent sunburn on captive orca has been documented by former *SeaWorld* ex-trainers (Ventre & Jett 2015). Tekoa was photographed (Figure 20) with a white substance on his melon and rostrum. It appears to be a white cream of some sort. It is unclear if this has been applied by the *Loro Parque* staff or is something that Tekoa has found in his tank and rubbed onto himself. If the former, it is ambiguous whether, if cream, it is to prevent sunburn or for another skin issue, as two of the veterinarians caring for the *Loro Parque* orca both stated that all the orca at *Loro Parque* had absolutely no health issues of any sort (see section 1. TEETH, above). This statement therefore implies that it is not necessary to treat any skin issues on Tekoa with cream or any other medication.

Regardless, there does seem to be some sort of skin abnormality as at the 'lip' area near the end of his rostrum, the skin has dried out in the extremely short time (seconds) that he had his head out of the water (Figure 20).

<sup>24</sup> <https://web.archive.org/web/20160621170713/http://www.holiday-weather.com/tenerife/averages/>

<sup>25</sup> <http://www.freemorgan.org/evidence-for-court/>



**Figure 11a.** Layout of the tanks at *Loro Parque*, Tenerife, Spain. North is to the top of the image and the medical tank, labelled, can be seen between the two holding tanks to the east and west. The medical tank dimensions are; depth 4.2m (13.8ft), width 7.1m (23.3ft) and length 12.4m (40.7ft). Note it is not clear if this includes the approximately 1m (3.3ft) wide ledge on the northern edge of the tank, which is typically at, or just below, the water level (see Figures 12a-b).



**Figure 11b.** The medical tank is located between the two holding tanks and the separation gates between the medical tank and the holding tanks can be seen. Part of the show tank under the canopy is visible. In this undated image the medical tank holds Victoria ('Vicky') a calf that was born in captivity (August 2012) at *Loro Parque*. She was rejected by her mother (Kohana) who was born in captivity at *SeaWorld* (USA). Vicky had to be hand raised and only survived for 10 months. During at least the first six months of her short life she was detained primarily alone and held nearly exclusively in the medical tank (until her death in June 2013). The oval tank in the bottom right is not connected in any way to the Orca Ocean tank system and it is used exclusively for bottlenose dolphins. Source: [www.fotosaereasdecanarias.com](http://www.fotosaereasdecanarias.com)





**Figure 12a.** Morgan on the raised floor of the medical tank at *Loro Parque*. Note the light colour of the floor, which is highly reflective of light, including UV, when raised and also when submerged. Also note that Morgan's rostrum extends over the edge of the ledge (which is approximately 1m (3.3ft) wide and visible to the right of the frame). There is limited space to the posterior of her tail, illustrating the small size of the tank. The medical tank dimensions are given by *Loro Parque* as; depth 4.2m (13.8ft), width 7.1m (23.3ft) and length 12.4m (40.7ft), but it is unclear if this includes the ledge. As of 28 April 2016, Morgan is 5.1m (16.7ft) long. Photos 12a & b sourced from *Loro Parque's* website<sup>26</sup> on 20160526, however the date and time the images were apparently taken is embedded in the photos (20150831).



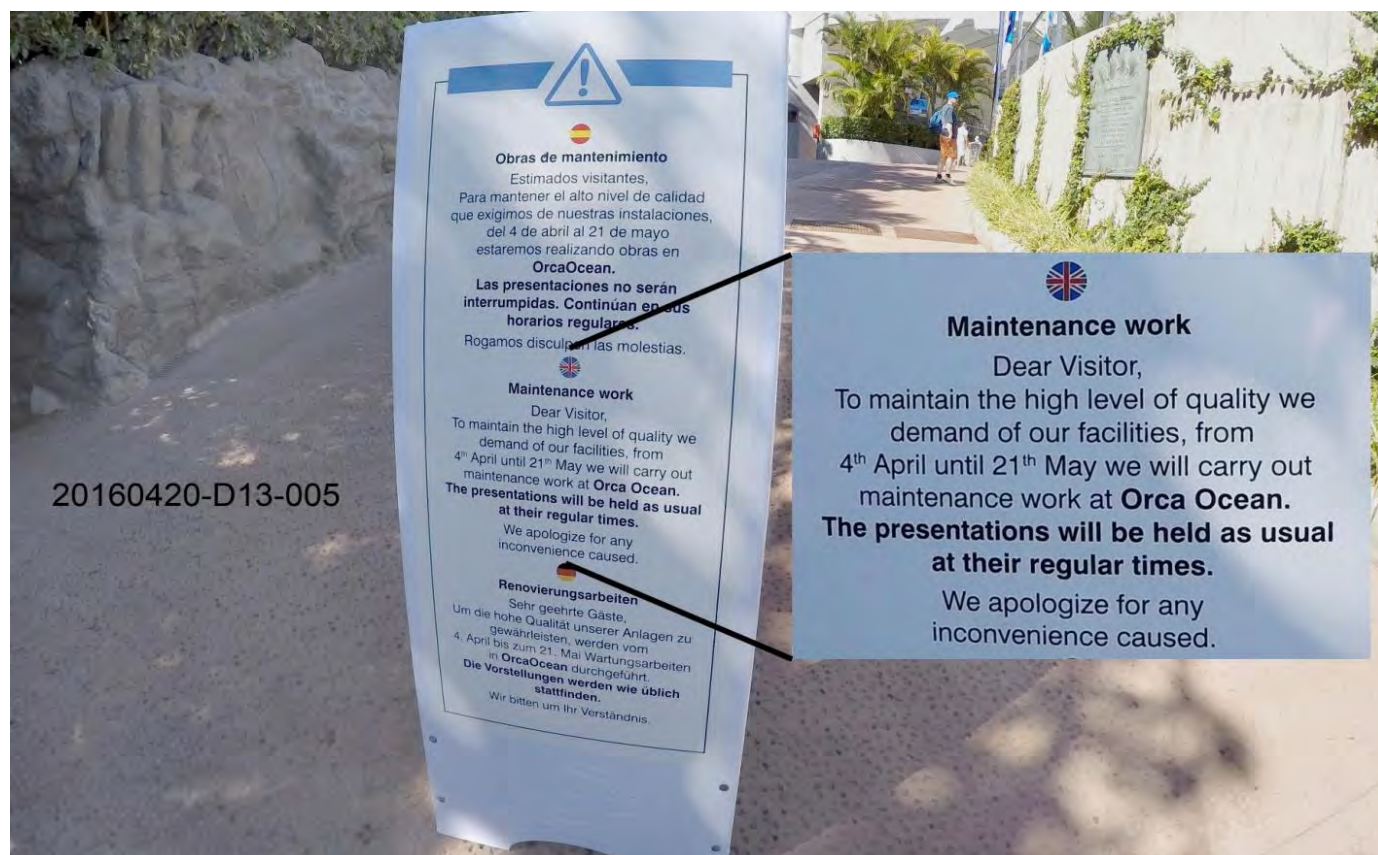**Figure 12b.** Morgan on the raised floor of the medical tank at *Loro Parque*. Refer to Figure 12a caption for details. Note at least one set of rake marks are visible on her right mandible and self-mutilation damage is visible on the tip of her mandibles.

<sup>26</sup> [https://web.archive.org/web/20160621170836/http://www.loroparque.com/morgan/hoy/index\\_en.html](https://web.archive.org/web/20160621170836/http://www.loroparque.com/morgan/hoy/index_en.html); images #7 & 8





**Figure 13.** Taken in September 2011 at *Loro Parque*, the medical tank holds two orca. The left, Tekoa (a male, who at that time was 11 years old) and right, Kohana (a female, who at that time was nine years old), lie in water too shallow for them to swim due to the floor being raised. The trainer at the rear (middle) holds the control for lowering the floor, whilst the two trainers in the foreground require the orca to ‘target’ (hold their rostrums to a small ball on the end of the pole).



**Figure 14.** Sign at the east entrance to Orca Ocean Stadium, *Loro Parque*, indicating that maintenance was conducted during the period 04 April-21 May 2016, (see also Figure 15, for maintenance work).





**Figure 15.** The water has been drained from the ‘Orca Ocean’ west tank, exposing the paint scheme during maintenance on 21 April 2016. The floor of the tank is painted the same pale blue colour as the walls. All tanks have a similar colour scheme, except the medical tank which has the same pale brown upper edge and the same pale blue walls, with an even paler coloured floor (see Figures 12a-b). Note the heavy pipe-metal segregation gate, open against the north wall of the tank and its scale compared to the painters (see close-up Figure 16).



**Figure 16.** The medical tank segregation gates are constructed with heavy pipe-metal and are at both the west and east ends. A sense of scale is perceived when comparing the main cross pipes to the similar thickness of the man’s arm (also see Figure 14). Based on the known dimensions of the medical tank, the gates are more than 4m (13.12ft) high and approx. 3m (9.84ft) wide.





**Figure 17.** Morgan (left, background), Tekoa (middle) and Adán (foreground, right) all in the medical tank during the 1645hr show on the 22 April 2016. Note the water level is down by approximately 0.5m (1.6ft) due to maintenance on adjoining (west) tank. Therefore the water depth in the medical tank is approximately 3.6m (11.8 ft). The lengths of Tekoa (at 15 years, 6 months old) and Adán (at 5 years, 6 months old) are not known to the authors, however, Morgan, who is known to be 5.1m (16.7ft) and approximately 9 years old when this photograph was taken, is between the two in size. *Loro Parque* consistently uses the medical tank as a holding tank during shows, which places unacceptable physical and social stressors on the orca.



**Figure 18.** On the 21 April 2016, Morgan was photographed, whilst locked in the medical tank, with her right eye closed and globules of mucus streaming from it.





**Figure 19.** The orca at *Loro Parque* were frequently photographed with their eyes closed when they had their heads raised above the water. It can only be speculated as to why this is, but lack of shade and the chemicals used to treat the water in the tanks should be considered. Two examples are given here with an open eye (left) next to the closed eye (right) of Keto (top) and Morgan (bottom).



**Figure 20.** Tekoa with the remains of a substance, that appears to be a cream, on his melon and rostrum. It is unclear if this is something that has been applied by the *Loro Parque* staff or is something foreign from the tank that Tekoa has rubbed onto himself. Tekoa can be identified by his damaged teeth – see Figure 8a.

## 4. BREEDING

On the 17 March 2016, *SeaWorld Entertainment Inc.*, the owner of at least five of the six orca, including all of the males<sup>27</sup> held at *Loro Parque*, made a statement that it would stop all breeding of its captive orca due to concerns by the public about the welfare issues of keeping these animals in captivity<sup>28</sup>. *SeaWorld*, in their company portfolio have<sup>29</sup> listed ownership of all six orca at *Loro Parque* and as the co-sponsor of this proposal, the *Humane Society US* has stated, that the breeding ban would apply to *Loro Parque*<sup>30</sup>. However, *Loro Parque*, despite not owning any of the orca held at its facility, has challenged that decision in their online public blog<sup>31</sup>.

*“....we understand that permanent prevention of the reproduction of wild animals under human care is an action that goes against the very cycle of life and well-being of the animals.”*

Although it is current industry standards to control breeding (of any captive species) through management of the individual animals, apparently *Loro Parque* is not in agreement. Management standard operating procedures may include separation of the sexes (permanently or during certain phases of the females cycle), physical contraceptives (e.g., castration) or chemical contraceptives. Only permanent separation of the sexes provides 100% guarantee that contraception will be effective. Whilst at *Loro Parque*, post the announcement by *SeaWorld*, Visser & Lisker observed the adult male Keto persistently pursuing Morgan (female), even when other females were present. The potential for a violation of the CITES transport permit (see Spiegl & Visser 2015, for details) and a ‘mistaken’ pregnancy to occur are naturally high when a sexually mature male is kept with a sexually mature female (Morgan has been reported to be ovulating<sup>32</sup>). Given that the ban on breeding by *SeaWorld* was a reflection of concerns regarding welfare, such breeding would be, clearly a compromise of welfare for this (or any) female held at *Loro Parque* as well as any resulting offspring.

## 5. MORGAN

Morgan was transferred to *Loro Parque* in November 2011. Since her transfer, concerns over various aspects of her welfare have been raised by members of the public, NGO’s, veterinarians and scientists. The recent observations (April 2016) by Visser & Lisker have illustrated, again, that there are welfare discrepancies between the official *Loro Parque* statements and the actual situation. The inconsistency regarding her teeth and the problems associated with locking her in the medical tank are described above. However, other concerns are behavioural and are from observing Morgan as an individual, as well as in comparison to the *SeaWorld* orca held captive at *Loro Parque*.

For instance, she has been observed ‘lunging’ high out of the water when coming to ‘station’ (Figure 21a). It is unclear why she does this, however such behaviour may indicate that Morgan is extremely hungry. Orca in captivity are typically kept at ‘optimum performance mode’ through control of their food, i.e., the amount of food provided each day is tightly controlled and limited (approximately 2–3% of their body

<sup>27</sup> The ownership of Morgan is under dispute – see Spiegl & Visser (2015) available from: <http://www.freemorgan.org/spiegl-visser-2015-white-paper-whale-laundering/>

<sup>28</sup> <https://web.archive.org/web/20160621171454/http://news.nationalgeographic.com/2016/03/160317-seaworld-orcas-killer-whales-captivity-breeding-shamu-tilikum/>

<sup>29</sup> <http://www.sec.gov/Archives/edgar/data/1564902/000119312513447594/d600440ds1.htm> page 76 (Our Animals) in SeaWorld Entertainment, Inc.’s SEC Form S-1 Statement, 20 November 2013

<sup>30</sup> <https://web.archive.org/web/20160630040633/http://www.takepart.com/article/2016/06/29/seaworld-deal-was-just-beginning>

<sup>31</sup> <https://web.archive.org/web/20160612215615/http://blog.loroparque.com/statement-aiza-about-announcement-seaworld/?lang=en>  
<https://web.archive.org/web/20160612215646/http://blog.loroparque.com/press-release/?lang=en>

<sup>32</sup> <http://www.freemorgan.org/vet-inspections/>



weight per day, Robeck et al. 2004, "Every week, we monitored their weight to make sure it was optimal." [page 40] Hargrove & Chua-Eoan 2015). The food volume is typically kept at a level to promote maximum adherence to commands (".... the whale's food was withheld for behavioral reasons—that is, to make sure the whales performed to SeaWorld's expectations." [page 76-77] Hargrove & Chua-Eoan 2015). Any orca which is satiated is less likely to respond to orders ("... overweight whales don't have appetites or an interest in food." [page 41] Hargrove & Chua-Eoan 2015). As such, orca in captivity are characteristically hungry and they often exhibit the institutionalized behaviour of 'begging' for food (swimming with their mouths open), when a trainer appears. 'Begging' is a behaviour that has not been reported in the scientific literature for wild orca.

Lunging behaviours such as those documented here can become dangerous for the other animals and the trainers. For example, Morgan has been photographed lunging up and leaning her chin on the safety rail (Figure 21b), which places her head at very near the height of a crouching trainer (see trainer in Figure 21c). Additionally, Morgan had been photographed lunging up above shoulder height of a trainer, which poses any number of issues *inter alia*, knocking a trainer over or if Morgan became aggressive, allowing her to easily grasp a trainer in her mouth and pull the trainer into the water.



**Figure 21a.** Morgan (rear) 'lunging' out of water to receive food at the eastern edge of the east tank. Keto (foreground) and Kohana (middle) are stationed in the 'typical' position, lower down in the water. Lunging behaviour such as this can become dangerous. It may also indicate that Morgan is extremely hungry. Morgan has a history of lunging out of the water (see Figure 21b-c).





**Figure 21b.** A historic (17 November 2013) image of Morgan lunging out of the water towards a trainer who is to the right, just out of frame. Morgan can be seen to be pressing up against the ‘safety rail’ with her chin. This evidence illustrates that her lunging behaviour has been ongoing for more than two years now. Morgan can be identified by her distinctive eye patch. Both Figures 21b-c are of the west tank.



**Figure 21c.** Morgan photographed (17 November 2013) lunging out of the water almost to the shoulder height of a trainer who is standing upright. This lunge is well above the head of the trainer who is crouching to Morgan’s right. In both instances there is a risk to the trainer should Morgan become aggressive or accidentally strike a trainer. The trainer in the middle of frame, looking over towards Morgan, is distracted. Note the other orca ‘stationed’ in a ‘typical’ position to the lower left of frame.

Furthermore, observations of Morgan with the other orca has shown that she is still subjected to excessive sexual pressure from at least one of the male orca (see details above). Morgan is often locked into the same tank (medical or other tanks) with the males and has no avenue for escape. Concerns were raised prior to her transfer regarding the dysfunctional nature of the group of orca held at *Loro Parque* and in 2012 about the welfare of Morgan specifically. Spiegl & Visser (2015) wrote the following in their report regarding whale laundering by *Dolfinarium Harderwijk*, *Loro Parque* and *SeaWorld*;

*“..... not the first time that concerns and complaints have been raised about Loro Parque. In a report from Suzanne M. Allee dated 10 October 2010, followed by a letter from Dr. Naomi Rose on behalf of The Humane Society of the US, Animal Welfare Institute and the Whale and Dolphin Conservation Society dated 11 November 2010, red flags were raised with the NMFS, but the warnings went unheeded. Now in 2015, in light of the presence of the rescued, wild-born Morgan and the fact that she is now sexually mature, the conflict at Loro Parque can no longer be ignored.”* [page 80].

We concur with this and add that the dental damage and the ongoing aggression at *Loro Parque* emphasise the very real concerns raised about these animals. Figure 22, taken 21 April 2016, shows at least two sets of teeth rake marks (bites) inflicted by the teeth of conspecifics. These injuries and the avoidance behaviour described below indicate that altercations are continuing despite assurances by *Loro Parque* that Morgan is fully integrated<sup>33</sup>. Rake marks on the other orca were also documented, but are not included here (images available upon request).



**Figure 22.** Rake marks (from orca teeth) on Morgan's left eye patch and on her ventral area, anterior to the flipper insertion point. Excessive rake marks from conflicts within the dysfunctional group of orca held at *Loro Parque* have been noted previously by Visser (2012).

<sup>33</sup> <http://www.freemorgan.org/wp-content/uploads/2012/10/Almunia-2012-report-on-the-introduction-of-a-rescued-orca-into-Loro-Parque.pdf>



Furthermore, Morgan has also been documented a number of times attempting to avoid contact with other orca, by completely leaving the water and hauling out onto the ledge surrounding the tank<sup>34</sup> (FMF unpublished data) and in at least one instance for an extended period<sup>35</sup> so that her skin dried out and she also had what appeared to be blood on her chin (see Figure 23). Tekoa, an orca with excessive rake marks and bites inflicted by the other orca at *Loro Parque*, to the extent where he is one of the most raked orca in captivity, world-wide, was also photographed and videographed exhibiting this same behaviour in April 2016<sup>36</sup> (e.g., see Figure 24).



**Figure 23.** Morgan hauled out on the ledge surrounding the west tank at *Loro Parque* on 22 February 2016. She remained out of the water for nearly 10 minutes and was in the sun that whole time. Video of her (from which this image is taken) shows her being commanded back into the water, but she soon returns to the ledge<sup>37</sup>. Note the red 'stripe' on her chin, which appears to be blood.



**Figure 24.** The orca Tekoa hauled out on the ledge surrounding the east tank at *Loro Parque*. Such abnormal behaviour is often associated with attempts to avoid conflict with other orca held in the tank, as there is limited space to escape. Tekoa, a male, is frequently attacked and is one of the most 'raked' (bitten) orca in captivity, worldwide. Note his dorsal fin has begun to collapse to his left side. This is an inherent issue for captive male orca as they reach maturity, which Tekoa is now doing at 15 years, 6 months old. 100% of adult male orca in captivity have collapsed dorsal fins (e.g., see Figures 26a, 27a-b, 28a, of the 20 year, 10 month old adult male known as 'Keto' at *Loro Parque*).

<sup>34</sup> <https://web.archive.org/web/20160621171642/http://news.nationalgeographic.com/2016/06/seaworld-orca-morgan-beaches-tenerife-canary-islands/>

<sup>35</sup> <https://web.archive.org/web/20160621171736/https://www.thedodo.com/morgan-orca-beaches-herself-1839101767.html>

<sup>36</sup> <https://web.archive.org/web/20160621171823/https://www.thedodo.com/seaworld-orca-morgan-beaching-herself-1847517890.html>

<sup>37</sup> <https://www.youtube.com/watch?v=hHLFiZm7g20>




The Visser (2012) report noted, *inter alia*, the frequency of attacks (Morgan was at least 100 times more likely to be attacked at *Loro Parque* than orca in another study) and the extent of the bite marks (Morgan was inflicted with more than 320 puncture and bite marks, all documented by photographs). She exhibited self-inflicted mutilations from abnormal and repetitive behaviours such as banging her head on the concrete walls – all of which are strong indicators that there is compromised welfare for this individual.

Because of the FMF's advocacy for Morgan (e.g., [www.freemorgan.org](http://www.freemorgan.org)) and our presentation of evidence in court, the staff at *Loro Parque* attempt to prevent further data collection each time the authors visit. Therefore, the evidence presented herein was severely limited by the behaviour of the training staff who, typically and almost immediately, moved Morgan into the medical tank each time the authors arrived into the stadium area prior to a show. By containing Morgan in the medical tank the staff severely restricted photographic opportunities. Moreover, the staff insisted that the authors could not take photographs in the public areas adjacent to the seating area of the stadium (i.e., alongside the east tank and closer to the medical tank). Attempts such as these are highly suggestive of a desire to hide any number of issues that would be revealed by clear photographs. Despite such endeavours to prevent data collection, a small number of images were collected of Morgan (e.g., of her teeth Figure 4a-b).


As illustrated in Figures 4a-b, Morgan has severely damaged teeth. Most of the damage is from self-mutilating behaviour in the form of the stereotypic chewing on the concrete. The authors documented Morgan conducting this behaviour on all three observation days. She was photographed conducting this behaviour in the east tank (Figure 25a), where the lowered water also allowed the authors to observe and photograph damage to the paint and concrete. This damage was apparently inflicted by the orca chewing and gnawing on the corner. Morgan has been documented and photographed chewing at that particular corner during previous observations (e.g., see Figure 25b from the 08 March 2014, where a small area of the concrete is also damaged and clearly visible).

When Morgan arrived at *Loro Parque* on the 29<sup>th</sup> of November 2011 her teeth had started to show apical wear due to the time she was held in the tiny concrete tank at *Dolphinarium Harderwijk*, Netherlands (Visser & Hardie 2011). However, from the time of her arrival at *Loro Parque* the extent and acceleration of damage increased exponentially (Figure 5). Visser (2012, Figure 22, page 23) described Morgan chewing on the concrete in an excessive manner and noted that the trainers stood by and watched. Similar observations were made by Visser & Lisker in April 2016 and Morgan was noted as chewing on the concrete in various areas of the Orca Ocean stadium (e.g., Figure 25a whilst in the east tank). It is apparent the barren concrete tanks of *Loro Parque* provide inadequate levels of stimulation for Morgan (and the other orca). The repetitive nature of the circus-like shows, the basic format of which has remained unchanged since the FMF has begun monitoring Morgan, provide nothing more stimulating than, at best, a slight or temporary distraction from the relentless boredom the animals suffer.

Concerns about Morgan's welfare have been raised ever since her capture and have escalated since her arrival at *Loro Parque*. The indicators of compromised welfare, other than dental damage, have included stereotypic pattern swimming, bobbing and catatonic-like behaviour so that at times Morgan was apparently unaware of her surroundings. This list does not address the aggression from the other orca which is a systemic problem with this dysfunctional group of captive orca. Clearly, based on these findings alone, the holding conditions at *Loro Parque* are substandard and indicate gross negligence. The welfare indicators observed in relation to Morgan, the only wild-born orca held captive at *Loro Parque*, highlight how extreme the situation is.



**Figure 25a.** Morgan attempting to chew on the concrete in the east tank. The lowered water level due to maintenance on the west tank, exposed a corner of the tank, to the right of Morgan (see enlarged area) that has been chewed by the orca (possibly Morgan herself), exposing the underlying blue paint and/or the concrete. Previous photographs (*e.g.*, see Visser 2012) have shown Morgan with blue paint on her teeth and Figure 25b shows Morgan in 2014 chewing the concrete in the area enlarged in this image.



**Figure 25b.** Morgan chewing on the concrete in the east tank. Despite the water level being higher in this 2014 photograph, a small section of concrete can be seen as damaged (see enlarged area). Note the gate, post and safety rail positions labelled in both photographs to allow cross referencing of Morgan's position and the area damaged in Figure 25a. The wooden maintenance separators are not present in this 2014 photograph, rather the water from the west tank is visible.

## 6. KETO

Keto, the oldest male held at *Loro Parque*, was born in captivity at *SeaWorld*, San Antonio on 17 June 1995 (*i.e.*, as of April 2016 he was 20 years, 10 months old). He was transferred to *Loro Parque* in February 2006 as a subadult male of 11 years old. Since that transfer his dorsal fin, like that of all adult male orca in captivity<sup>38</sup>, has collapsed completely. With that collapse have come signs of skin issues such as excessive sloughing in the area slightly anterior to and under the dorsal fin (Figure 26a-d). Such build-up of sloughing skin is apparently a result of poor hydrodynamics due to the collapse of the fin. Typically, a state of self-cleaning of the skin in cetaceans is facilitated by the epidermal surface of the skin including intercellular gel formation and water flow (Baum *et al.* 2003) but this is apparently interrupted by the subsidence of the fin.

Keto also exhibits ‘pock marks’ of unknown origin which are clearly visible on the paler pigmentation of his saddle patch (Figure 28a-b). On the 22 April 2016 he also had two patches of skin anomalies on his right caudal peduncle (between the flank patch and the fluke inserts) that aetiology of these injuries is unknown and they may be from a skin disease or from rubbing against a hard surface (Figure 29a-b). They appear to be comprised of lesions in various stages of either recovery or development as some parts appear paler in discolouration than others and in at least one instance one of the paler patches appears to be developing over the top of the darker coloured area Figure 29b).

On two days of observations (20 & 21 April 2016), Keto was photographed with an area of ‘wrinkled’ skin on his left lateral thorax, above his pectoral fin insert (Figures 29a-b). Although cetacean skin has gross and histological differences in structure compared to terrestrial mammal skin, such wrinkling is extremely atypical in cetaceans (wild or captive). Dermal ridges and dermal papillae are recognized by the authors as part of the natural structure of cetacean epidermis, however these are microscopic in nature (Jones & Pfeiffer 1994) and as a result are not visible in such a way that they could be clearly seen in a photograph taken from over 50m away. It should be pointed out that the wrinkles on Keto’s skin were not a direct facet/result of light reflection (although light reflection does allow them to be observed clearly), as he was photographed on two different days, at two different positions on the slide-out (*i.e.*, at 90° to the water and parallel to it). Nor were the wrinkles only present due to flexing of his body, as they are still visible when he was flexed slightly to his left and to his right (see Figures 30a-b for examples).

It is unclear if such wrinkling on Keto’s skin is indicative of electrolyte imbalances or the initial stages of dehydration, however given that the wrinkling is only clearly visible on an isolated area of his body there is likely to be some other underlying issue(s) at hand. Regardless, the cause cannot be confirmed without further diagnostics, including standard serum chemistry and complete blood count panels assessed through an accredited laboratory and only if bloods were taken and analysed on these particular days.

<sup>38</sup> <http://www.seaworldfactcheck.com/dorsalfin.htm>





**Figure 26a.** Keto on the 'slide out' during a show on 20 April 2016. This photograph includes part of his collapsed dorsal fin to facilitate correct identification. Figure 26b shows a close up under his dorsal fin.



**Figure 26b.** Keto, a close up of the area under the dorsal fin, showing rough and sloughing skin.





**Figure 27a.** Keto, whilst swimming (head to left of frame), showing the area under the dorsal fin, with rough and sloughing skin indicative of skin issues in cetaceans. (See Figure 27b for comparison).




**Figure 27b.** Keto, whilst swimming. Photograph taken nine seconds after Figure 27a, to show that the rough and sloughing skin is not just a manifestation of reflections or other light properties.





**Figure 28a.** Keto on the 'slide out' during a show on 20 April 2016. This photograph includes his collapsed to facilitate identification. His left saddle patch area shows extensive 'pock-marking' (see Figure 28b).



**Figure 28b.** Keto, a close up of the saddle patch area showing 'pock-marked' skin. See text for discussion.





**Figure 29a.** Keto, tail flukes and caudal peduncle out of the water. This photograph includes part of his curled flukes and under tail pigmentation to facilitate correct identification. Figure 29b shows a close up of the area on the caudal peduncle that shows skin issues.



**Figure 29b.** Keto, a close up of the area between the flank patch (white) and the tail fluke inserts, showing rough and sloughing skin indicative of skin issues in cetaceans.





**Figure 30a.** Keto on the 'slide out' during a show on 20 April 2016. This photograph includes the unique 'eye patch' to facilitate correct identification and his collapsed dorsal fin can be seen at the top right.




**Figure 30b.** Keto, a close up of the lateral thorax area (above the pectoral fin insert) showing 'wrinkled' skin. See text for discussion.





**Figure 30c.** Keto on the 'slide out' during a show a day later (i.e., on 21 April 2016). This photograph includes the unique 'eye patch' and his collapsed dorsal fin to facilitate correct identification. Note that he is more parallel to the water (*i.e.*, orientated differently from his position in Figure 30a-b).



**Figure 30d.** Keto, a close up of the lateral thorax area (above the pectoral fin insert) showing 'wrinkled' skin from a different angle, albeit less than visible in Figure 30b. See text for discussion.

## 7. CONCLUSIONS

Despite continued assurances by *Loro Parque* that 'all is well' for the *SeaWorld* orca and Morgan the wild-born orca, the data presented here is indicative, once again, that there are underlying and fundamental issues that compromise the welfare of these orca. The very same welfare indicators identified by the captivity industry, as markers for compromised welfare, are prevalent and excessive at *Loro Parque* and violations of the most basic animal welfare standards and measurements, which the facility purports to adhere to, are in clear view for all to see.

Given that legitimate concerns have been well documented, over a period of years, there is clearly a need for an assessment to be conducted by authorities external to any political influence. Assessments by local authorities are not identifying the very same issues that can be seen by anyone who stands in the public viewing areas. Health assessments by a veterinarian (who has a long-standing history with *Loro Parque*) and by those currently working at the facility, show extreme divergence from the documented evidence collected from the public viewing areas.

Such discrepancies are alarming and suggest a basic and systemic problem of non-independent scrutiny. Additionally, inspectors do not appear to have the essential understanding of wild-orca behaviour and/or an extensive overview of captive-orca facilities and therefore seem to either not recognize or seem to overlook the welfare issues seen at *Loro Parque*.

Without a completely independent assessment, it is impossible to ascertain the full extent of the compromised welfare of these animals. Such an assessment should be carried out over a number of days and not be restricted by access (*i.e.*, not restricted to show times nor to only the location of the public viewing area) and should only be conducted by an expert very experienced with wild and captive orca behaviour as well as welfare. Furthermore, a thorough and open-book inspection of the daily behavioural records, the daily feeding schedules and the detailed medical records and any other relevant notes regarding each individual will help to clarify those welfare issues identified but also to discover additional welfare issues that are not necessarily apparent from observations of the animals themselves.

There are many who are calling for an end to keeping this species in captivity. The industry is hearing more and more from the public about their concerns for the welfare of these sentient beings. The evidence presented here is yet another argument to illustrate why they, as a species and as individuals, are unsuitable for maintaining as zoo animals, show animals or any other form of captivity.

**We call upon *SeaWorld* and *Loro Parque* to recognize the prevalence of the compromised welfare indicators identified herein. We ask for them to acknowledge that at *Loro Parque* the animals' welfare is severely undermined and that immediate attention must be given to address the situation. We strongly suggest that they place these six orca into a seaside sanctuary, where they can continue to receive the medical care they will require with these injuries, but in which they can experience the natural ocean, large enclosures, reduced stress and by default, their welfare will be enhanced. The FMF offers its help for such a project as we believe in working towards improving conditions for the orca. In particular, removing these orca from the concrete tanks they are locked in will help to prevent even further damage to their teeth. To do otherwise would only be disingenuous and hypocritical of *SeaWorld's* and *Loro Parque's* claims to be doing the best for these animals and to be companies that give priority to animal welfare.**



**APPENDIX 1.** Summary of details regarding damaged teeth of the six orca held at *Loro Parque*. Details and comparisons between the Greenwood inspection and our observations are given in Appendix 2.

Orca	Sex	Dentition Summary	Figure(s)
Adán	♂	At least <b>1</b> tooth now <b>broken</b> At least <b>8, possibly 9</b> teeth now <b>drilled</b> At least <b>6</b> teeth <b>worn to gum</b> At least <b>1</b> tooth <b>nearly worn to gum</b> At least <b>3</b> teeth with <b>severe apical wear</b> At least <b>2</b> teeth with <b>moderate apical wear</b>	3a-d
Morgan	♀	At least <b>4, possibly 5</b> teeth now <b>broken</b> At least <b>1</b> tooth likely <b>drilled</b> At least <b>2, possibly 3</b> teeth <b>worn to gum</b> At least <b>1</b> tooth <b>nearly worn to gum</b> At least <b>7</b> , teeth with <b>severe apical wear</b> At least <b>6</b> teeth with <b>moderate apical wear</b>	4a-b
Sykla	♀	At least <b>1</b> tooth now <b>missing</b> At least <b>4, possibly 5</b> teeth now <b>broken</b> At least <b>8</b> teeth now <b>drilled</b> At least <b>3</b> teeth <b>worn to gum</b> At least <b>2</b> teeth <b>nearly worn to gum</b> At least <b>5, possibly 6</b> teeth with <b>severe apical wear</b> At least <b>2</b> teeth with <b>moderate apical wear</b> At least <b>3</b> teeth <b>starting to show apical wear</b>	6a-f
Kohana	♀	At least <b>4, possibly 5</b> teeth now <b>broken</b> At least <b>5</b> teeth now <b>drilled</b> At least <b>1</b> tooth <b>worn to gum</b> At least <b>2</b> teeth <b>nearly worn to gum</b> At least <b>3</b> teeth with <b>severe apical wear</b> At least <b>2</b> teeth with <b>moderate apical wear</b> At least <b>1</b> tooth <b>possibly starting to show apical wear</b>	7a-d
Tekoa	♂	At least <b>1</b> tooth, <b>possibly 3</b> , now <b>broken</b> At least <b>7</b> teeth now <b>drilled</b> At least <b>4</b> teeth <b>worn to gum</b> At least <b>1</b> tooth <b>nearly worn to gum</b> At least <b>3</b> teeth with <b>severe apical wear</b> At least <b>4</b> teeth with <b>moderate apical wear</b> At least <b>2</b> teeth <b>starting to show apical wear</b>	8a-d
Keto	♂	At least <b>4</b> teeth now <b>missing</b> At least <b>10</b> teeth now <b>broken</b> At least <b>7</b> teeth now <b>drilled</b> At least <b>4</b> teeth <b>worn to gum</b> At least <b>2</b> teeth <b>nearly worn to gum</b> At least <b>2</b> teeth with <b>severe apical wear</b> At least <b>2</b> teeth with <b>moderate apical wear</b> At least <b>3</b> teeth <b>starting to show apical wear</b>	9a-e
<b>ALL SIX SEAWORLD ORCA HELD AT LORO PARQUE</b>		At least <b>5</b> teeth now <b>missing</b> At least <b>24</b> teeth, <b>possibly 29</b> , now <b>broken</b> At least <b>36, possibly 37</b> teeth now <b>drilled</b> At least <b>20, possibly 21</b> teeth <b>worn to gum</b> At least <b>9</b> teeth <b>nearly worn to gum</b> At least <b>23, possibly 24</b> teeth with <b>severe apical wear</b> At least <b>18</b> teeth with <b>moderate apical wear</b> At least <b>8</b> teeth, <b>possibly 9</b> <b>starting to show apical wear</b>	See above

**APPENDIX 2.** Details of dentition of orca held at *Loro Parque*, Tenerife, Spain. Comparisons between veterinarian Andrew Greenwood’s “Health Assessment” inspection (conducted 29 September 2015, emphasis added) and our documentation by photographs (conducted 20-22 April 2016) are given, along with a summary and comments. Age is calculated as of 20 April 2016. See Table 1 for photographic examples of categories and definitions of terms. L = left, R = right, teeth are numbered sequentially from the front of the mouth.

ORCA	AGE & SEX	GREENWOOD (veterinarian) 29 September 2015	PHOTOGRAPHS 20-22 April 2016	SUMMARY & COMMENTS “now” = 22 April 2016
Adán	♂  5 years, 6 months, 8 days	“Several teeth in his lower jaw showed wear down to the pulp level, but <u>only one had been drilled open</u> , the rest being still vital. <u>One tooth was broken.</u> ”	<p>(<b>mandible L1</b>) worn to gum  (<b>mandible L2, L3</b>) drilled, worn to gum  (<b>mandible L4</b>) broken (fractured, splintered into parts), (previously drilled), worn to gum (gum overgrowth)  (<b>mandible L5</b>) drilled, severe apical wear  (<b>mandible L6</b>) moderate apical wear</p> <p>(<b>mandible R1</b>) likely drilled, worn to gum  (<b>mandible R2</b>) drilled, exposed red tissue (pulp), worn to gum  (<b>mandible R3</b>) drilled, nearly worn to gum  (<b>mandible R4, R5</b>) drilled, severe apical wear, buccal surface worn to gum  (<b>mandible R6</b>) moderate apical wear</p>	<p>At least <b>1</b> tooth now <b>broken</b>  At least <b>8, possibly 9</b> teeth now <b>drilled</b>  At least <b>6</b> teeth <b>worn to gum</b>  At least <b>1</b> tooth <b>nearly worn to gum</b>  At least <b>3</b> teeth with <b>severe apical wear</b>  At least <b>2</b> teeth with <b>moderate apical wear</b></p> <p>(i.e., since Greenwood inspection only 7 months prior, further damage documented = at least <u>8 more teeth drilled and 6 worn to the gum</u>)</p> <p>See Figures 3a-3d</p>
Morgan	♀  Approx. 9 years	“Five teeth in the lower jaw were worn to the pulp level but not drilled out, and <u>two were broken.</u> ”	<p>(<b>mandible L1, L2, L3, L4, L5, L6</b>) severe apical wear (NOTE: details of amount of damage not discernible)  (<b>mandible L7</b>) broken (chipped, lingually and/or mesially), moderate apical wear  (<b>mandible L8</b>) moderate apical wear</p> <p>(<b>mandible R0</b>) vestigial, worn to gum (see Figure 11b for details)  (<b>mandible R1, R2</b>) worn to gum  (<b>mandible R3</b>) likely drilled, nearly worn to gum  (<b>mandible R4</b>) severe apical wear, pulp spot visible  (<b>mandible R5</b>) broken (fractured, split in half), moderate apical wear  (<b>mandible R6</b>) broken (chipped, lingual surface), moderate apical wear  (<b>mandible R7</b>) broken (chipped, distal surface), moderate apical wear  (<b>mandible R8</b>) moderate apical wear  (<b>mandible R9</b>) broken (chipped lingual &amp;/or anterior surfaces) &amp;/or severe apical wear</p>	<p>At least <b>4, possibly 5</b> teeth now <b>broken</b>  At least <b>1</b> tooth likely <b>drilled</b>  At least <b>2, possibly 3</b> teeth <b>worn to gum</b>  At least <b>1</b> tooth <b>worn nearly to gum</b>  At least <b>7</b>, teeth with <b>severe apical wear</b>  At least <b>6</b> teeth with <b>moderate apical wear</b></p> <p>(i.e., since Greenwood inspection only 7 months prior, further damage documented = at least <u>2, possibly 3 more teeth broken, 1 drilled, 2 worn to the gum and 1 worn nearly to the gum, 2 more to the pulp (severe apical wear)</u>)</p> <p>NOTE: Morgan’s moved by staff to prevent documentation of left teeth. <b>More teeth may be broken than recorded here.</b> <i>Loro Parque</i> vets claimed on 22 April 2016 that this orca had NO broken teeth (see text section 1. TEETH for discussion).</p> <p>See Figures 4a-b</p>



APPENDIX 2 continued. Details of dentition of orca held at Loro Parque, Tenerife, Spain.

ORCA	AGE & SEX	GREENWOOD (veterinarian) 29 September 2015	PHOTOGRAPHS 20-22 April 2016	SUMMARY & COMMENTS “now” = 22 April 2016
Skyla	♀ 12 years, 2 months, 2 days	“Tooth damage included eight worn with open cavities, one missing, and <u>one broken</u> with secondary dentine formation.”	<p>(<b>mandible L1</b>) drilled, worn to gum  (<b>mandible L2</b>) possibly broken (chipped, apex) &amp;/or severe apical wear  (<b>mandible L3</b>) broken (fractured, lingual surface missing), drilled, severe apical wear  (<b>mandible L4</b>) severe apical wear, pulp spot  (<b>mandible L5</b>) broken, (chipped, lingual surface), drilled, severe apical wear  (<b>mandible L6</b>) broken (chipped, lingual surface), drilled, moderate apical wear  (<b>mandible L7</b>) apical wear starting</p> <p>(<b>mandible R1, R2</b>) drilled, worn to gum  (<b>mandible R3</b>) drilled, apical wear nearly to gum  (<b>mandible R4</b>) missing  (<b>mandible R5</b>) drilled, apical wear nearly to gum  (<b>mandible R6</b>) moderate apical wear, likely drilled  (<b>mandible R7, R8</b>) apical wear starting</p> <p>(<b>maxillae L2</b>) broken (apical-basal crack), severe apical wear &amp; protrusion into gum/gum overgrowth</p>	<p>At least <b>1</b> tooth now <b>missing</b>  At least <b>4</b>, <b>possibly 5</b> teeth now <b>broken</b>  At least <b>8</b> teeth now <b>drilled</b>  At least <b>3</b> teeth <b>worn to gum</b>  At least <b>2</b> teeth <b>worn nearly to gum</b>  At least <b>4</b>, <b>possibly 6</b> teeth with <b>severe apical wear</b>  At least <b>3</b> teeth with <b>moderate apical wear</b>  At least <b>3</b> teeth <b>starting to show apical wear</b></p> <p>(i.e., since Greenwood inspection only 7 months prior, further damage documented = at least <u>3 (possibly 4) more teeth broken, 8 drilled, 3 worn to the gum and 2 nearly worn to the gum with another 5, possible 6 with severe apical wear</u>)</p> <p>See Figures 6a-f</p>
Kohana	♀ 13 years, 11 months, 19 days	“Most of her lower teeth at the front were worn at the side, but only five had open pulp cavities. The lower right 5th tooth had an infected socket and was under treatment.” [misspelt as Kohanna]	<p>(<b>mandible L1</b>) drilled, worn to gum  (<b>mandible L2</b>) drilled, nearly worn to gum  (<b>mandible L3</b>) nearly worn to gum  (<b>mandible L4</b>) broken (chipped, lingual surface), nearly worn to the gum on buccal surface  (<b>mandible L5</b>) broken (chipped, apex), moderate apical wear  (<b>mandible L9</b>) tip possibly broken off &amp;/or started to show apical wear</p> <p>(<b>mandible R1</b>) broken (crack, vertical buccal surface), drilled, severe apical wear  (<b>mandible R2, R3</b>) drilled, severe apical wear, buccal surface worn to gum  (<b>mandible R4</b>) broken (chipped, lingual surface) moderate apical wear, buccal surface worn to the gum  (<b>mandible R5</b>) moderate apical wear</p>	<p>At least <b>4</b>, <b>possibly 5</b> teeth now <b>broken</b>  At least <b>5</b> teeth now <b>drilled</b>  At least <b>1</b> tooth <b>worn to gum</b>  At least <b>2</b> teeth <b>worn nearly to gum</b>  At least <b>3</b> teeth with <b>severe apical wear</b>  At least <b>2</b> teeth with <b>moderate apical wear</b>  At least <b>1</b> tooth <b>possibly starting to show apical wear</b></p> <p>(i.e., since Greenwood inspection only 7 months prior, further damage documented = at least <u>4, possibly 5 teeth now broken, 5 drilled, 1 worn to the gum and 2 nearly worn to the gum and 3 with severe apical wear</u>)</p> <p>See Figures 7a-d</p>

**APPENDIX 2 continued.** Details of dentition of orca held at *Loro Parque*, Tenerife, Spain.

ORCA	AGE & SEX	GREENWOOD (veterinarian) 29 September 2015	PHOTOGRAPHS 20-22 April 2016	SUMMARY & COMMENTS “now” = 22 April 2016
Tekoa	♂ 15 years, 5 months, 13 days	“showed some tooth damage, having <u>seven</u> worn teeth which had been <u>drilled</u> open, two of which had closed off the cavity with secondary dentine regrowth.”	<p>(mandible L1) worn to gum (mandible L2) drilled, worn to gum (mandible L3 &amp; L4) drilled, severe apical wear (mandible L5) possibly broken (chipped, lingual), moderate apical wear (mandible L6) moderate apical wear (mandible L7) apical wear starting</p> <p>(mandible R1) worn to gum (mandible R2) drilled, worn to gum (mandible R3) drilled, nearly worn to gum (mandible R4) possibly broken (chipped, distal surface), drilled, severe apical wear (mandible R5) drilled, severe apical wear (mandible R6, R7) moderate apical wear</p> <p>(maxillae R1) broken (chipped, apex buccal surface) (maxillae R3) started to show apical wear)</p>	<p>At least <b>1</b> tooth, <b>possibly 3</b>, now <b>broken</b> At least <b>7</b> teeth now <b>drilled</b> At least <b>4</b> teeth <b>worn to gum</b> At least <b>1</b> tooth worn <b>nearly to gum</b> At least <b>3</b> teeth with <b>severe apical wear</b> At least <b>4</b> teeth with <b>moderate apical wear</b> At least <b>2</b> teeth <b>starting to show apical wear</b></p> <p>(i.e., since Greenwood inspection only 7 months prior, further damage documented = at least <u>1</u> tooth, <u>possibly 3</u> now broken, <u>4</u> worn to the gum and <u>1</u> nearly to the gum)</p> <p>See Figures 8a-d</p>
Keto	♂ 20 years, 10 months, 4 days	“showed some tooth damage which was under continuing treatment. Seven lower front teeth were worn and their dead pulp cavities had been drilled out and widened to allow regular flushing to prevent infection. <u>Two such teeth had collapsed</u> and small pieces had fallen out or been removed. Keto was also missing four upper teeth on his left side (which had occurred more than ten years ago before arrival at Loro Parque).”	<p>(mandible L1) drilled, nearly worn to gum (mandible L2) broken (cracked, vertical buccal surface), drilled, nearly worn to gum (mandible L3) broken (cracked, vertical buccal surface &amp; possible vertical crack on mesial lingual surface) &amp; (chipped, distal surface, apex), drilled, severe apical wear (mandible L4) broken (chipped, lingual &amp; distal surfaces), severe apical wear (mandible L5) broken (chipped, lingual surface), moderate apical wear (mandible L6) started to show apical wear</p> <p>(mandible R1) drilled, worn to gum (mandible R2, R3) broken (fractured &amp; collapsed), drilled, worn to gum (mandible R4), drilled, worn to gum, gum intrusion (mandible R5) moderate apical wear (mandible R6) started to show apical wear</p> <p>(maxillae L1) broken (cracked, vertical mesial surface, started to show apical wear) (maxillae L2, L3) broken (chipped, apex buccal surface) (maxillae L4, L5, L6, L7) missing</p> <p>(maxillae R1) apical wear starting (maxillae R5) broken (chipped apex)</p>	<p>At least <b>4</b> teeth now <b>missing</b> At least <b>10</b> teeth now <b>broken</b> At least <b>7</b> teeth now <b>drilled</b> At least <b>4</b> teeth <b>worn to gum</b> At least <b>2</b> teeth worn <b>nearly to gum</b> At least <b>2</b> teeth with <b>severe apical wear</b> At least <b>2</b> teeth with <b>moderate apical wear</b> At least <b>3</b> teeth <b>starting to show apical wear</b></p> <p>(i.e., since Greenwood inspection only 7 months prior, further damage documented = at least <u>6</u> more teeth broken and at least <u>2</u> more worn to the gum)</p> <p>See Figures 9a-e</p>



**APPENDIX 3.** Ranking of damage to each tooth (in mandible only). Escalating acuteness of damage = Undamaged, Minimal, Moderate and Severe. When a tooth was damaged with multiple types of injuries the most severe ranking was applied. When a tooth could not be ranked unambiguously, the less acute category was applied. Teeth that were not visible were ranked as Undamaged. Vestigial teeth were not used in % calculation. See text for details. We have used the median of 12 teeth per side of the mandible and given % of teeth showing Severe & Moderate damage combined. Tooth damage transposed from Appendix 2. L = Left, R = Right. N/A = not applicable, S = Severe, Mod = Moderate, Min = Minimal, U = Undamaged and/or Unknown.

ADÁN	(L0)	L1	L2	L3	L4	L5	L6	L7	L8	L9	L10	L11	L12	%
	N/A	S	S	S	S	S	Mod	U	U	U	U	U	U	50%
	(R0)	R1	R2	R3	R4	R5	R6	R7	R8	R9	R10	R11	R12	
	N/A	S	S	S	S	S	Mod	U	U	U	U	U	U	50%
MORGAN	(L0)	L1	L2	L3	L4	L5	L6	L7	L8	L9	L10	L11	L12	
	N/A	S	S	S	S	S	S	Mod	U	U	U	U	U	66.66%
	(R0)	R1	R2	R3	R4	R5	R6	R7	R8	R9	R10	R11	R12	
	S	S	S	S	S	S	S	Mod	S	U	U	U	U	75%
SKYLA	(L0)	L1	L2	L3	L4	L5	L6	L7	L8	L9	L10	L11	L12	
	N/A	S	S	S	S	S	Mod	Min	U	U	U	U	U	50%
	(R0)	R1	R2	R3	R4	R5	R6	R7	R8	R9	R10	R11	R12	
	N/A	S	S	S	S	S	S	Mod	Min	U	U	U	U	58.33%
KOHANA	(L0)	L1	L2	L3	L4	L5	L6	L7	L8	L9	L10	L11	L12	
	N/A	S	S	Mod	S	S	U	U	U	Min	U	U	U	41.66%
	(R0)	R1	R2	R3	R4	R5	R6	R7	R8	R9	R10	R11	R12	
	N/A	S	S	S	S	Mod	U	U	U	U	U	U	U	41.66%
TEKOA	(L0)	L1	L2	L3	L4	L5	L6	L7	L8	L9	L10	L11	L12	
	N/A	S	S	S	S	S	Mod	Min	U	U	U	U	U	50%
	(R0)	R1	R2	R3	R4	R5	R6	R7	R8	R9	R10	R11	R12	
	N/A	S	S	S	S	S	Mod	Mod	U	U	U	U	U	58.33%
KETO	(L0)	L1	L2	L3	L4	L5	L6	L7	L8	L9	L10	L11	L12	
	N/A	S	S	S	S	S	Min	U	U	U	U	U	U	41.66%
	(R0)	R1	R2	R3	R4	R5	R6	R7	R8	R9	R10	R11	R12	
	N/A	S	S	S	S	Mod	Min	U	U	U	U	U	U	41.66%

**APPENDIX 4.** Clegg et al. (2015)<sup>39</sup> criteria and measures for the welfare of captive bottlenose dolphins. The criteria used were based on "*evidenced potential for application to other species in managed care*". Therefore, all the criteria used to assess bottlenose dolphins are applicable to orca.

<b>C-Well® Criterion</b>	<b>C-Well® Measure</b>
1 Absence of prolonged hunger	1.1 Body Condition Score 1.2 Frequency of weight measurements 1.3 Dietary records
2 Absence of prolonged thirst	2.1 Capillary refill time 2.2 Hydration protocol
3 Resting comfort	3.1 Time budget
4 Thermal comfort	4.1 Frequency of water temperature testing 4.2 Water temperature and diet 4.3 Shade
5 Appropriate environment	5.1 Topography 5.1.1 Echolocation 5.1.2 Complexity of enclosure 5.2 Ability to exhibit complex movements 5.2.1 Swim speed 5.2.2 Aerials 5.3 Water quality 5.3.1 Salinity 5.3.2 Coliform 5.3.3 pH 5.3.4 Chlorine 5.3.5 Frequency of water quality testing 5.4 Enrichment 5.4.1 Application of enrichment
6 Absence of injuries	6.1 Total wound threshold 6.2 Wounds from enclosure
7 Absence of disease	7.1 Respiratory system 7.1.1 Frequency of coughing 7.1.2 Inhalation duration 7.2 Eye diseases 7.2.1 Discolouration 7.2.2 Squinting 7.3 Skin diseases 7.3.1 Skin abnormalities 7.3.2 Mouth abnormalities 7.4 Blood parameters 7.4.1 Blood sampling protocol
8 Absence of pain induced by management procedures	8.1 Blood draw 8.2 Gastric tubing 8.3 Voluntary restraint 8.4 Emergency containment training
9 Expression of social behaviours	9.1 Presence of social behaviours
10 Absence of abnormal behaviours	10.1 Stereotypic behaviour
11 Positive human-animal relationship	11.1 Response to trainer while not under stimulus control 11.2 Non-food tactile interactions

<sup>39</sup> Adapted from Table 1 in: Clegg, I. L. K., Borger-Turner, J. L., & Eskelinen, H. C. (2015). C-Well: The development of a welfare assessment index for captive bottlenose dolphins (*Tursiops truncatus*). *Animal Welfare*, 24(24).



## REFERENCES

- Baird, R. W. 1987. Foraging behavior and ecology of transient killer whales (*Orcinus orca*). Doctor of Philosophy, Simon Fraser University, Canada 173 pp.
- Barrett-Lennard, L. G., C. O. Matkin, J. W. Durban, E. Saulitis and D. K. Ellifrit. 2011. Predation on gray whales and prolonged feeding on submerged carcasses by transient killer whales at Unimak Island, Alaska. MARINE ECOLOGY PROGRESS SERIES 421:229-241.
- Baum, C., F. Simon, W. Meyer, L. G. Fleischer, D. Siebers, J. Kacza and J. Seeger. 2003. Surface properties of the skin of the pilot whale *Globicephala melas*. Biofouling 19:181-186.
- Bolwig, N. 1964. Facial expression in primates with remarks on a parallel development in certain carnivores (a preliminary report on work in progress). Behavioural Brain Research 22:167 - 192.
- Botreau, R., I. Veissier, A. Butterworth, M. B. M. Bracke and L. J. Keeling. 2007. Definition of criteria for overall assessment of animal welfare. Universities Federation for Animal Welfare 16: 225-228.
- Boyde, A. 1980. Histological studies of dental tissues of odontocetes. Reports of the International Whaling Commission 3:65-88.
- Christensen, I. 1982. Killer whales in Norwegian coastal waters. Report of the International Whaling Commission 32:633-642.
- Christensen, I. 1984. Growth and reproduction of killer whales, *Orcinus orca*, in Norwegian coastal waters. Report of the International Whaling Commission Special Issue 6:253-258.
- Clegg, I. L. K., J. L. Borger-Turner and H. C. Eskelinen. 2015. C-Well: The development of a welfare assessment index for captive bottlenose dolphins (*Tursiops truncatus*). Animal Welfare 24:267-282.
- Couquiaud, L. 2005. Special Issue: Survey of cetaceans in captivity. Aquatic Mammals 31:277-385.
- Fleming, M. and C. C. Burn. 2014. Behavioural assessment of dental pain in captive Malayan sun bears (*Helarctos malayanus*). Animal Welfare 23:131-140.
- Foote, A. D., J. Newton, S. B. Piertney, E. Willerslev and T. P. Gilbert. 2009. Ecological, morphological and genetic divergence of sympatric North Atlantic killer whale populations. Molecular Ecology 18:5207-5217.
- Ford, J. K. B. and G. M. Ellis. 1999. Transients: Mammal-hunting killer whales. University of British Columbia Press, Vancouver.
- Ford, J. K. B., G. M. Ellis, L. G. Barrett-Lennard, A. B. Morton, R. S. Palm and K. C. Balcomb. 1998. Dietary specialization in two sympatric populations of killer whales (*Orcinus orca*) in coastal British Columbia and adjacent waters. Canadian Journal of Zoology-Revue Canadienne de Zoologie 76:1456-1471.
- Ford, J. K. B., G. M. Ellis, C. O. Matkin, M. Wetklo, H. L. G. Barrett-Lennard and R. E. Withler. 2011. Shark predation and tooth wear in a population of northeastern Pacific killer whales. Aquatic Biology 11:213-224.
- Graham, M. S. and P. R. Dow. 1990. Dental care for a captive killer whale, *Orcinus orca*. Zoo Biology 9:325-330.
- Hargrove, J. and H. Chua-Eoan. 2015. Beneath the Surface: Killer whales, Seaworld, and the truth beyond Blackfish. St Martin's Press.
- Hoelzel, A. R. 1991. Killer whale predation on marine mammals at Punta Norte, Argentina; Food sharing, provisioning and foraging strategy. Behavioral Ecology and Sociobiology 29:197-204.
- Iñíguez, M. A., V. P. Y. Tossenberger and C. Gasparrou. 2002. Cooperative hunting and prey handling of killer whales in Punta Norte, Patagonia, Argentina. Pages 18 Fourth International Orca Symposium, September 23 - 28, 2002. Noirt, France.
- Jacobsen, J. K. 1986. The behavior of *Orcinus orca* in the Johnstone Strait, British Columbia. in B. C. Kirkevold and J. S. Lockard eds. *Behavioral biology of killer whales*. Zoo Biology Monographs. Alan R. Liss, New York.
- Jefferson, T. A., M. A. Webber and R. L. Pitman. 2008. Marine mammals of the world. A comprehensive guide to their identification. Academic Press, Amsterdam.
- Jett, J. and J. Ventre. 2015. Captive killer whale (*Orcinus orca*) survival. Marine Mammal Science.
- Jett, J. S. and J. M. Ventre. 2012. Orca (*Orcinus orca*) captivity and vulnerability to mosquito-transmitted viruses. Journal of Marine Animals and Their Ecology 5:9-16.
- Jones, F. M. and C. J. Pfeiffer. 1994. Morphometric comparison of the epidermis in several cetacean species. Aquatic Mammals:20-29.
- Loch, C., M. V. Swain, L. J. Van Vuuren, J. A. Kieser and R. E. Fordyce. 2013. Mechanical properties of dental tissues in dolphins (Cetacea: Delphinoidea and Iniioidea). Archives of Oral Biology 58:773-779.
- Loch Santos Da Silva, C. 2013. Morphology, structure and evolution of teeth in fossil and modern odontocetes (Cetacea) (Thesis, ). Retrieved from Doctor of Philosophy PhD, University of Otago.
- Lopez, J. C. and D. Lopez. 1985. Killer whales (*Orcinus orca*) of Patagonia, and their behavior of intentional stranding while hunting nearshore. Journal of Mammalogy 66:181-183.

- Martinez-Levasseur, L. M., D. Gendron, R. J. Knell, E. A. O'toole, M. Singh and K. Acevedo-Whitehouse. 2011. Acute sun damage and photoprotective responses in whales. *Proceedings of the Royal Society, B Biological Sciences* 278:1581-1586.
- Mellor, D. J. 2015a. Enhancing animal welfare by creating opportunities for positive affective engagement. *New Zealand Veterinary Journal* 63:3-8.
- Mellor, D. J. 2015b. Positive animal welfare states and encouraging environment-focused and animal-to-animal interactive behaviours. *New Zealand Veterinary Journal* 61.
- Mellor, D. J. 2015c. Positive animal welfare states and reference standards for welfare assessment. *New Zealand Veterinary Journal* 61:17-23.
- Mellor, D. J. and K. J. Stafford. 2001. Integrating practical, regulatory and ethical strategies for enhancing farm animal welfare. *Australian Veterinary Journal* 79:762-768.
- Mitchell, E. and A. N. Baker. 1980. Age of reputedly old killer whale, *Orcinus orca*, 'Old Tom' from Eden, Twofold Bay, Australia. Report of the International Whaling Commission.
- Morgan, K. N. and C. T. Tromborg. 2007. Sources of stress in captivity. *Applied Animal Behaviour Science* 102:262-302.
- Neves Dos Reis, M. 2014. Temporal change in the calling behaviour of an isolated killer whale (*Orcinus orca*). MSc, Universidade do Porto, 71 pp.
- Perrin, W. F. and A. F. Myrick. 1980. Age Determination of Toothed Whales and Sirenians. . Pages 229. Reports of the International Whaling Commission.
- Robeck, T. R., K. J. Steinman, S. Gearhart, T. R. Reidarson, J. F. McBain and S. L. Monfort. 2004. Reproductive physiology and development of artificial insemination technology in killer whales (*Orcinus orca*). *Biology of Reproduction* 71:650-660.
- Spiegl, M. and I. N. Visser. 2015. CITES and the Marine Mammal Protection Act: Comity and Conflict at Loro Parque. Free Morgan Foundation. 129 pp.
- Ulmer, F. a. J. 1941. Notes on a killer whale (*Grampus orca*) from the coast of New Jersey. *Notulae Nature of the Academy of Natural Sciences of Philadelphia* 83:1-5.
- Vapnek, J. and M. Chapman. 2010. Legislative and regulatory options for animal welfare. Food and Agriculture Organization of the United Nations (FAO Legal Office). 34 pp.
- Ventre, J. and J. Jett. 2015. Killer whales, theme parks and controversy: An exploration of the evidence. Pages 128-145 in K. Markwell ed. *Animals and tourism. Understanding diverse relationships*. Aspects of Tourism. Channel View Publications, UK.
- Visser, I. N. 2012. Report on the physical & behavioural status of Morgan, the wild-born Orca held in captivity, at Loro Parque, Tenerife, Spain. Free Morgan Foundation. 35 pp.
- Visser, I. N. and T. M. Hardie. 2011. "Morgan" the orca can and should be rehabilitated. With additional notes on why a transfer to another 'captive orca facility' is inappropriate and release is preferred. Orca Research Trust, Unpublished Report. 68 pp.
- Waller, B. M. and J. Micheletta. 2013. Facial Expression in Nonhuman Animals. *Emotion Review* 5:54-59.
- Werth, A. J. 2000. Feeding in marine mammals. Pages 475-514 in K. Schwenk ed. *Feeding: form, function and evolution in tetrapod vertebrates (Pp 537)*. Academic Press, San Diego, California, USA.
- Yano, K. and M. E. Dahlheim. 1995. Behavior of killer whales *Orcinus orca* during longline fishery interactions in the southeastern Bering Sea and adjacent waters. *Fisheries Science* 61:584-589.