

Attack on Morgan
(she is partially hidden)



Tooth rake marks on Morgan
(from other orca)

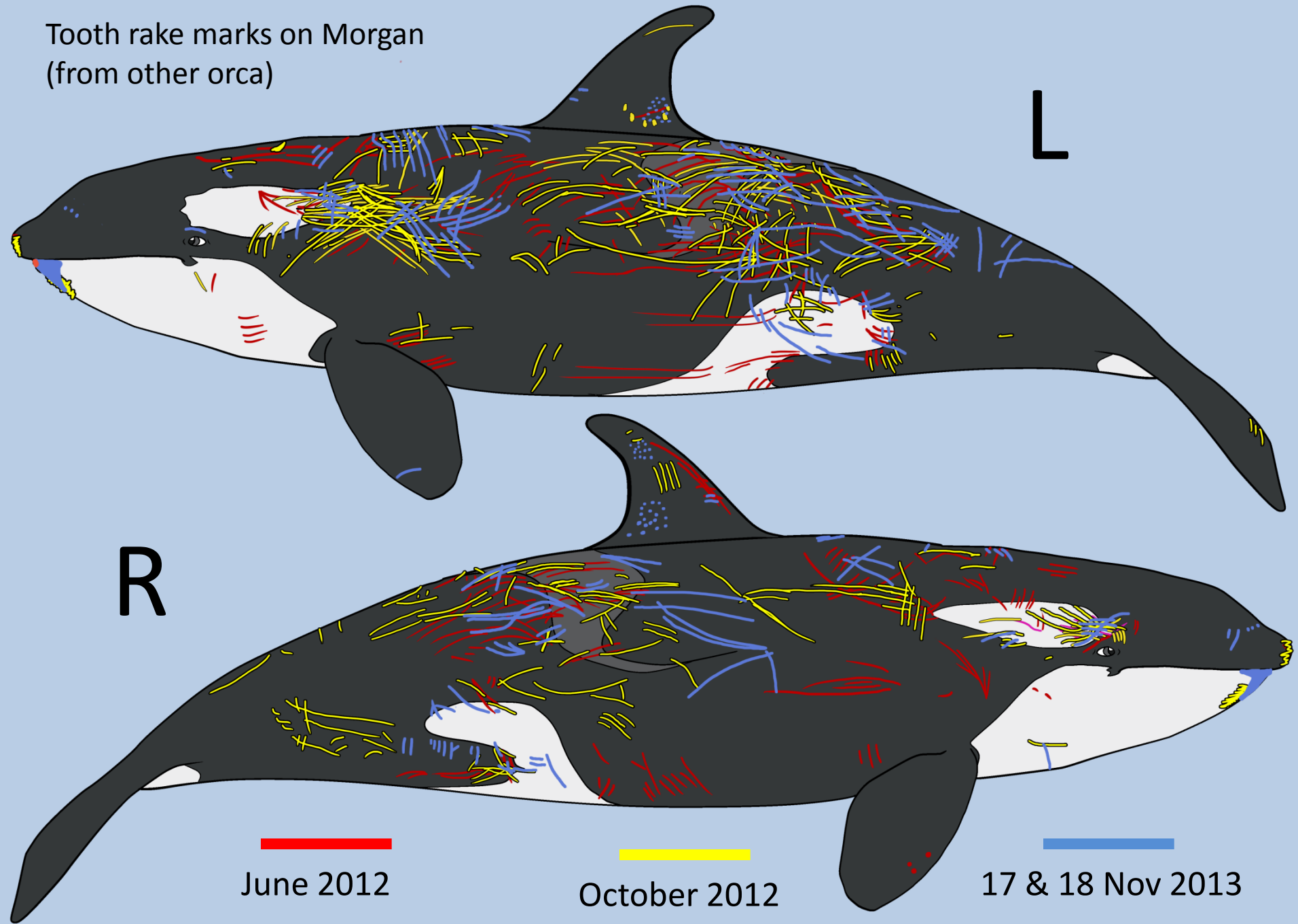
L

R

June 2012

October 2012

17 & 18 Nov 2013




(Dr Greenwood, Veterinarian, 20 Nov 2013)

“None of these scars had caused depigmentation, indicating that the wounds had been superficial.”



11 Nov 1998




14
June
1997

NOTE: white scar (indicated by arrow) is from a 'blister' and would be considered 'superficial'

HOWEVER: large cut into dorsal fin, which completely slices fin in half, is certainly not 'superficial'

11 Nov 1998



14
June
1997



15 Oct 1999



White superficial
'blister' scar is
still visible 11
years later

23 Oct 2008

HOWEVER, on cut of split
dorsal fin, the skin has
completely healed over
(NO depigmentation)



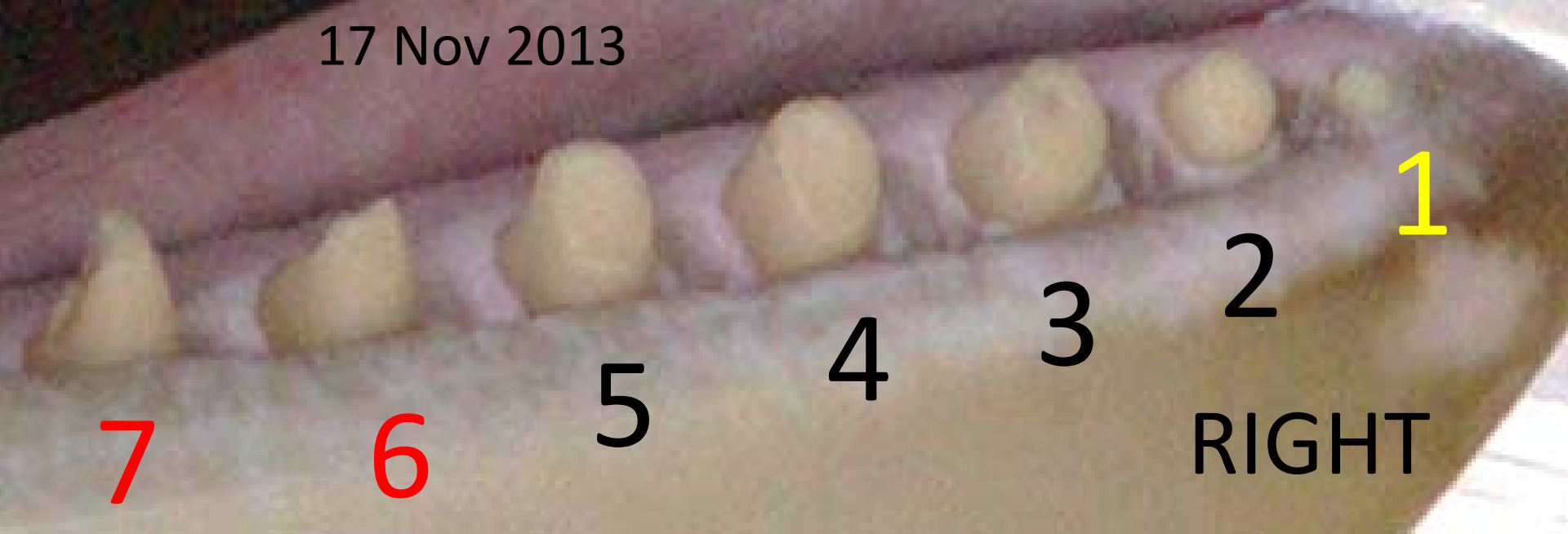CONCLUSION: Vet is not familiar with injuries of this kind, or is distorting truth,
because depigmentation is NOT indicative of severity of wounds

“cuts and abrasions were caused by the other whales in the pool; none of these was considered to need medical treatment”

(Greenwood, 20 Nov 2013)

This is uninformed, as such cuts and abrasions have caused death in captive cetacean before – this has been published in scientific peer-reviewed papers, which I can supply if you are interested in this aspect of malpractice.

17 Nov 2013



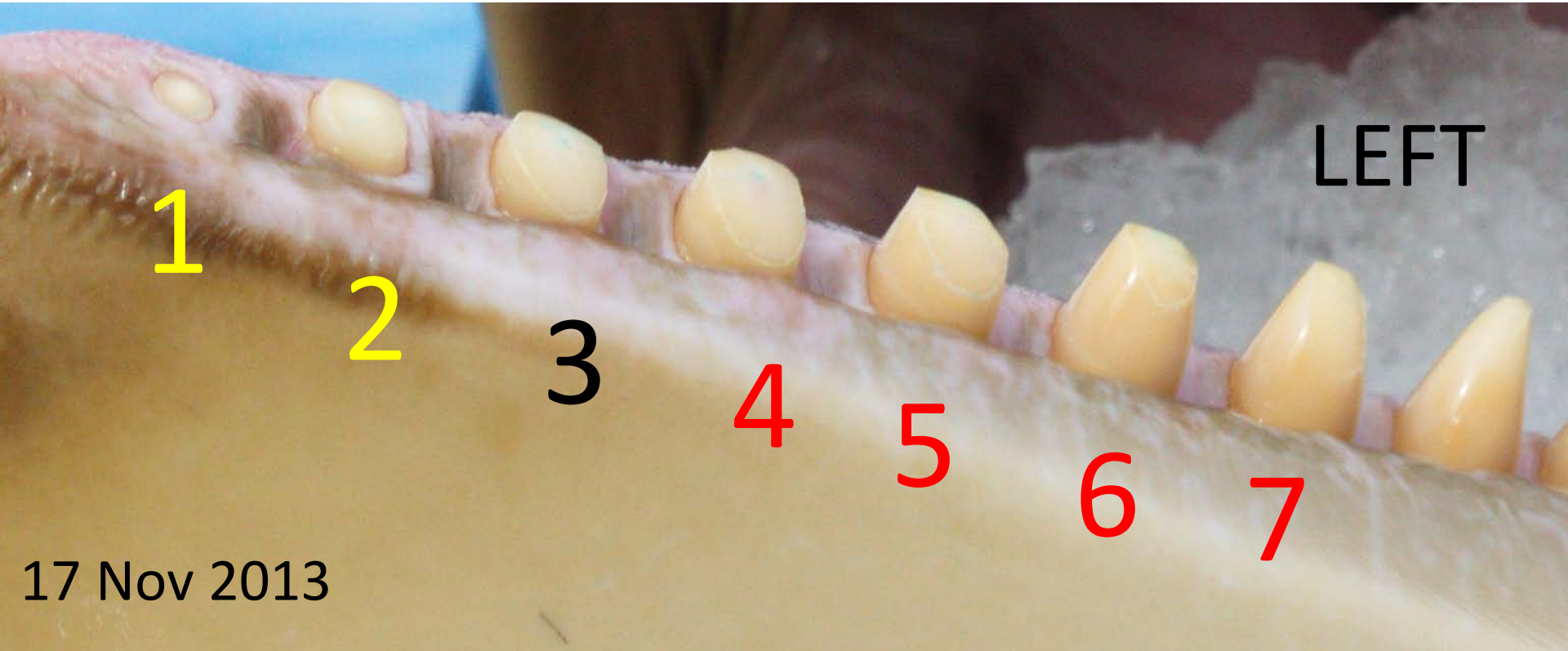
*“Morgan's front teeth were **partially worn**, seven at the front of the right mandible (lower jaw),.....”* (Dr Greenwood, 20 Nov 2013)

HOWEVER, he fails to acknowledge that tooth 1 is completely worn to the gum and that teeth 6 & 7 are badly broken. Additionally tooth #3 is about to be worn to the point where the pulp is about to be exposed – which will require drilling and daily (painful) flushing.

CONCLUSION: Vet is not familiar with assessing teeth, or is distorting truth, because these at least three of these teeth are more than ‘partially worn’. Any independent vet would ascertain that they are grossly worn and badly damaged, not ‘partially worn’.

“ *and three on the left.*”

(Greenwood, 20 Nov 2013)



HOWEVER, again, he fails to acknowledge that tooth 1 is completely worn to the gum and that teeth 4,5,6 & 7 area also worn (some badly). Additionally, again tooth #3 is about to be worn to the point where the pulp is about to be exposed – which will require drilling.

CONCLUSION: Vet is not familiar with counting to 7, assessing teeth, or is distorting truth, because these teeth are more than 'partially worn' and more teeth than he claims, are damaged. Again, any independent vet would ascertain that they are grossly worn and damaged

“When left unattended she showed no sign of repetitive or other abnormal behaviour.”

(Greenwood, 20 Nov 2013)

Although it is entirely possible that Greenwood never saw any stereotypies (abnormal or repetitive behaviours), he does not state how long he observed Morgan for (he should observe for days, not minutes), nor under what circumstances (had she just been released out of the tiny medical tank where they keep her locked for hours, was she just given a ‘toy’ to play with so she had something to ‘do’) = any number of biases could be introduced to ‘prevent’ an observation of these behaviours.

However, if Morgan was locked into the medical tank, which they repeatedly do, for hours at a time (I’ve got undercover video that shows this + see last page) or if she was left alone for hours (which they do), then she shows these behaviours. E.g., witnessed and photographed just three days before Greenwoods report (see next slide, Morgan chewing on the concrete in the medical tank where she had been locked for more than 1 hour, before, during and after a show). She chewed the tank repetitively.

“When left unattended she showed no sign of repetitive or other abnormal behaviour.”

(Greenwood, 20 Nov 2013)

17 Nov 2013 (time frame 4 min & 45 sec)
chewing on average every 71 sec



STEREOTYPIC BEHAVIOUR



**June
2012**



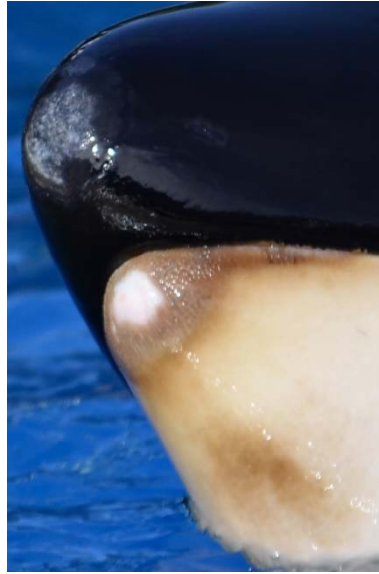**Oct
2012**



**Nov
2013**



**June
2012**



**Oct
2012**

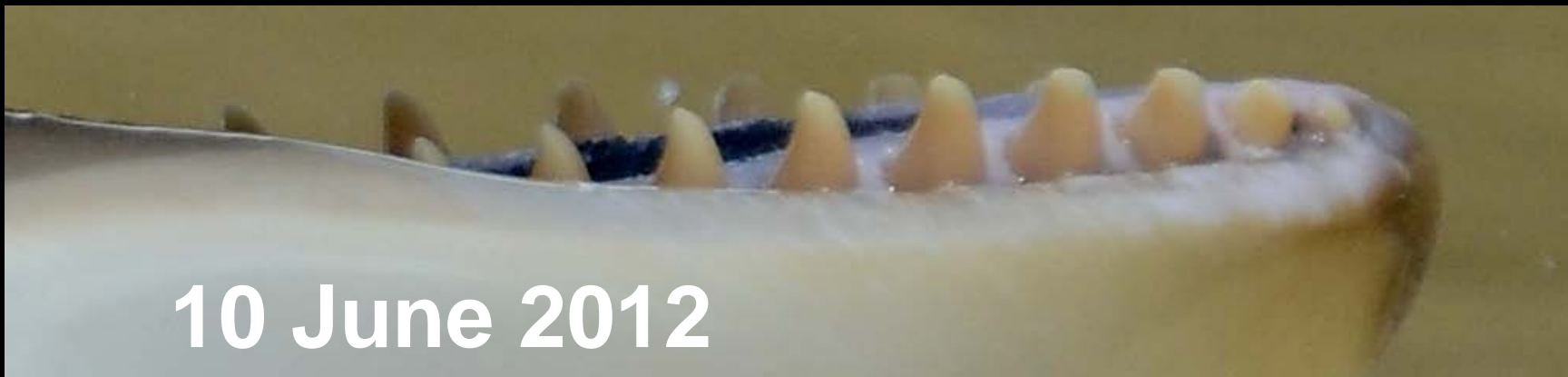

**Nov
2013**

'... if they [stereotypies] occupy much time, say 10% of the waking life, the conditions could be said to be bad for the welfare of the animal.'

Broom (1983) Stereotypies as Animal Welfare Indicators

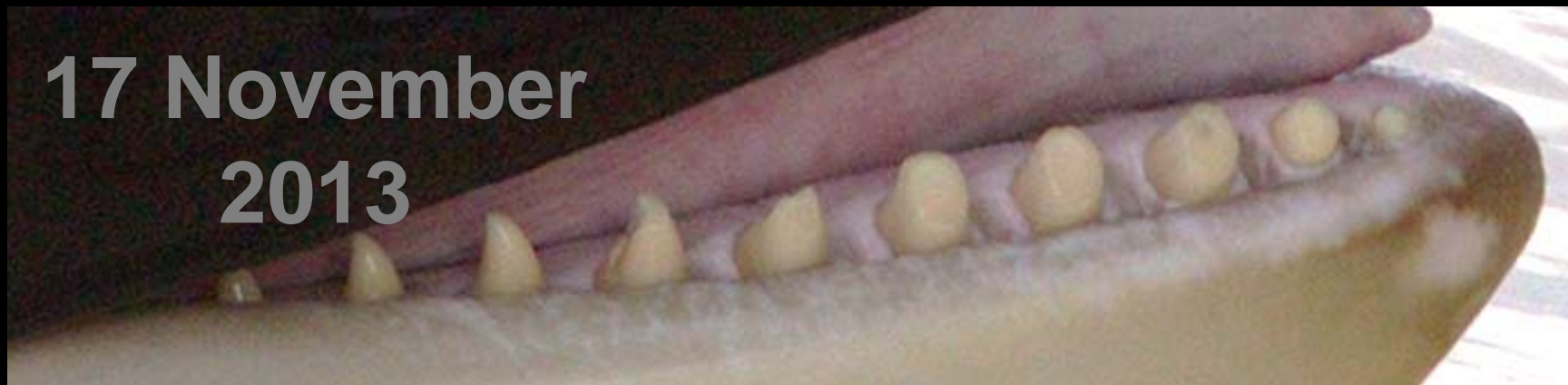Current Topics in Veterinary Medicine and Animal Science Volume 23, 1983, pp 81-87



10 June 2012



22 October 2012



**17 November
2013**

Blue Paint

Gingivitis



4

3

2

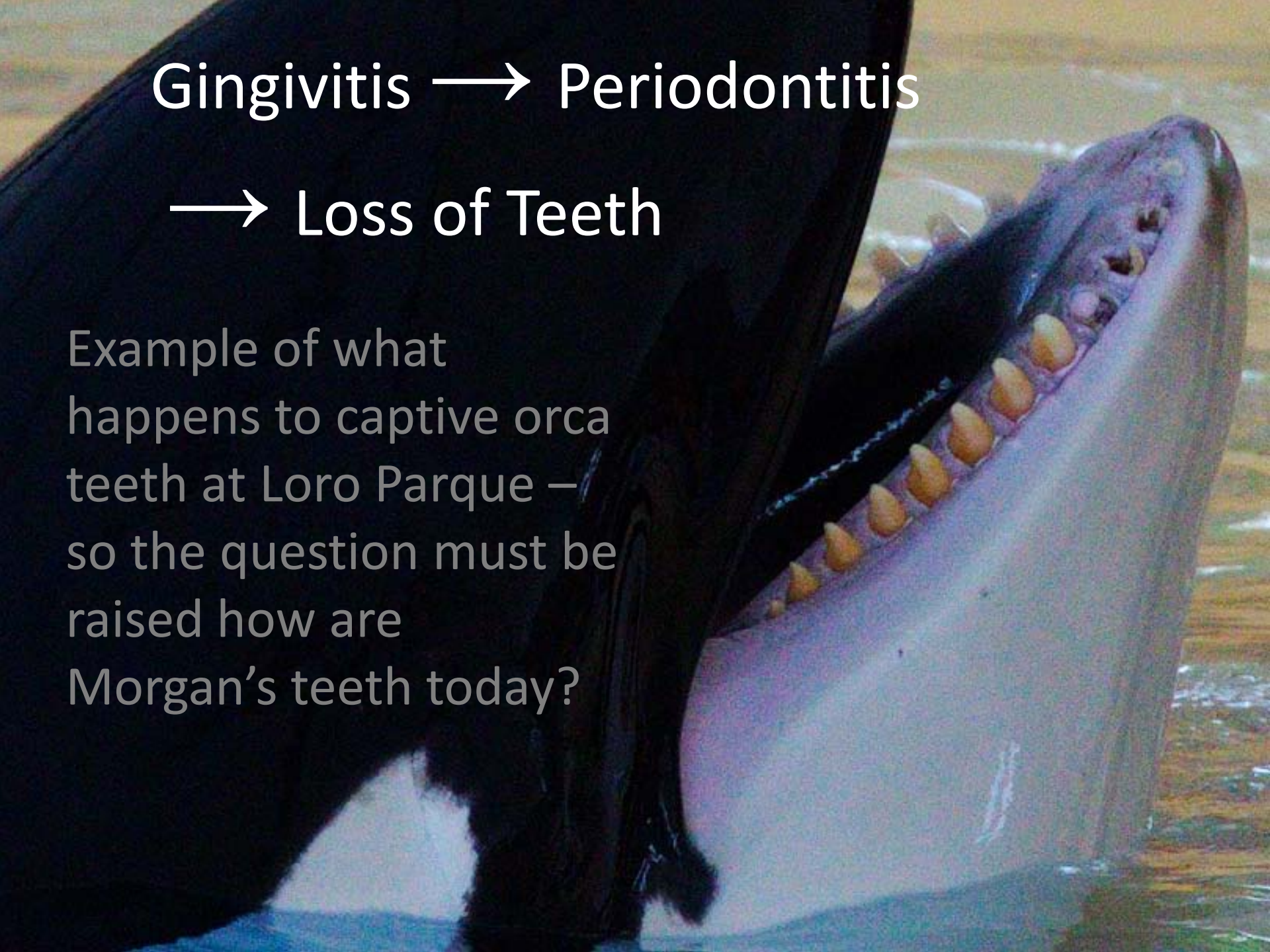
RIGHT

Tooth 3 also has the beginnings of the pulp exposed. This will require drilling (done with out anesthetic) and will require daily (painful) flushing to prevent infections.

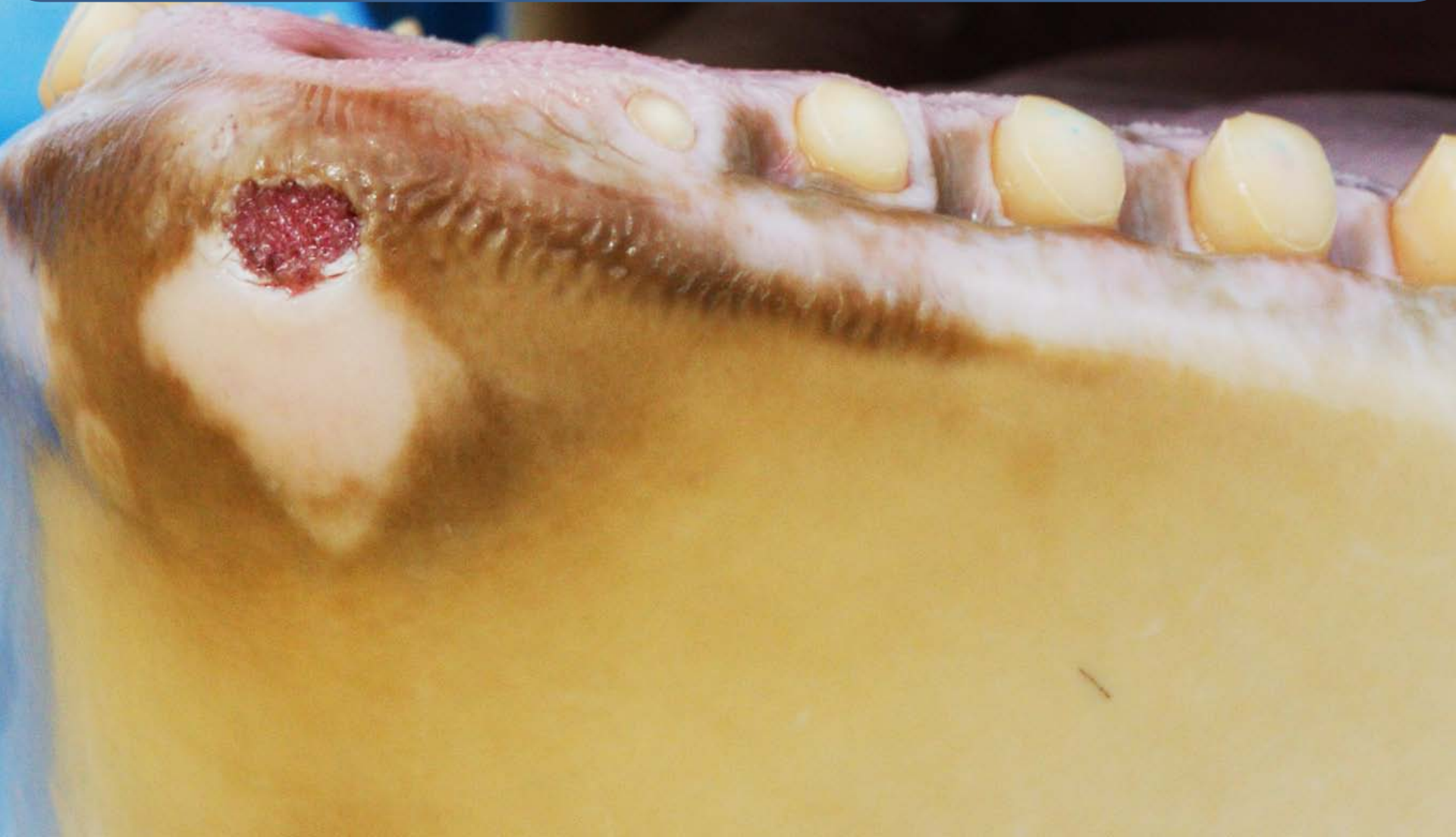Gingivitis → Periodontitis

→ Loss of Teeth

Example of what happens to captive orca teeth at Loro Parque – so the question must be raised how are Morgan's teeth today?




Self-inflicted damage on Morgan. The open wound as well as the white area (previously damaged 'hypertrophic tissue damage') were totally ignored by Loro Parque's Vet and not mentioned in his 'report'. However, they are an obvious and graphic sign of abnormal and repetitive behaviour. Resulting from banging her head against the concrete and chewing the concrete.



Dimensions of the
'medical tank' at
Loro Parque
It is smaller than
the tank at
Dolfinarium
Harderwijk
She is kept locked
in here for hours
at a time (see last
page for more details)

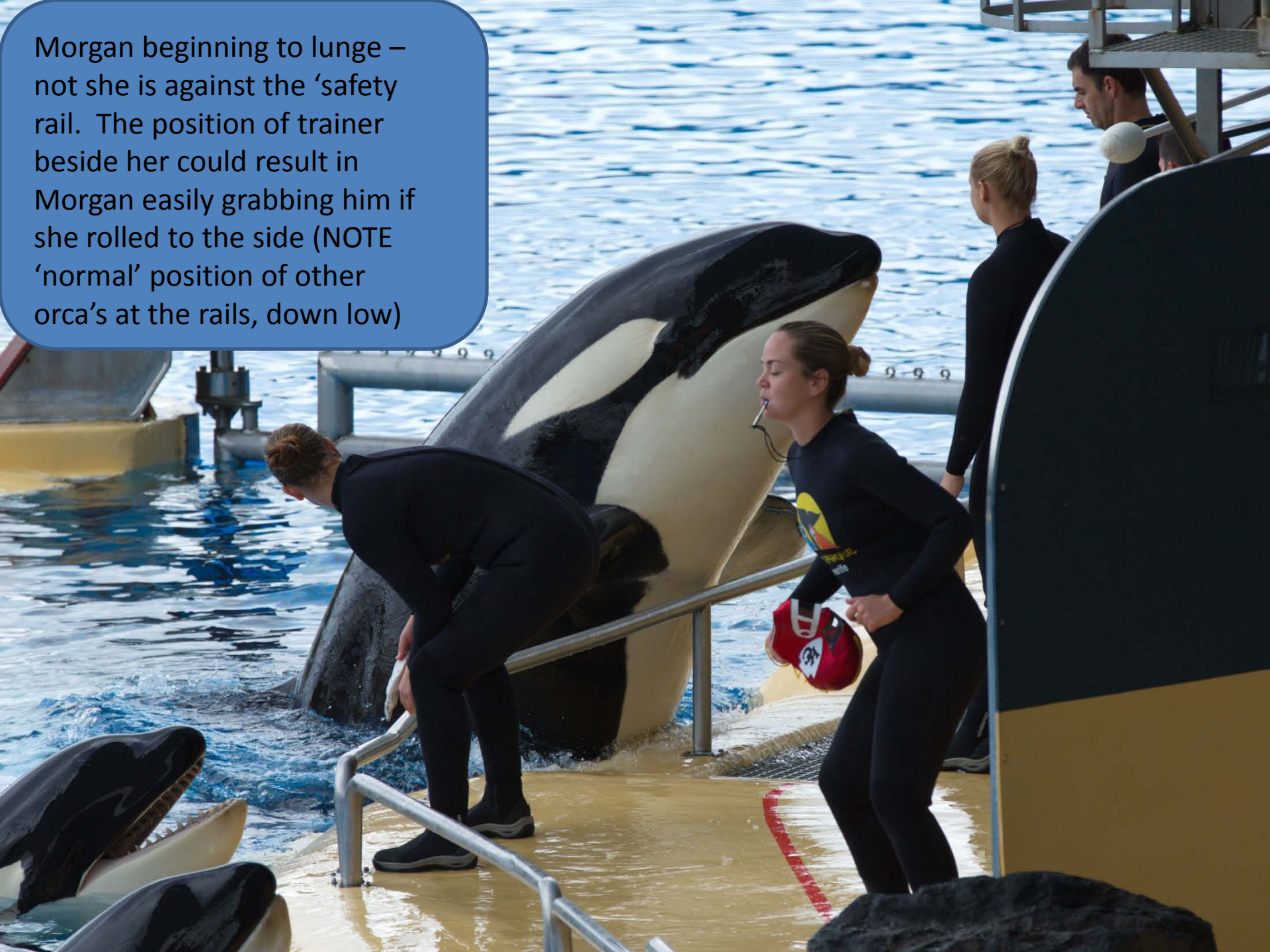Morgan = 4.74m (in 2013)

Tank Depth = 4.2m




Tank = Width 7.1 m, Length 12.4 m

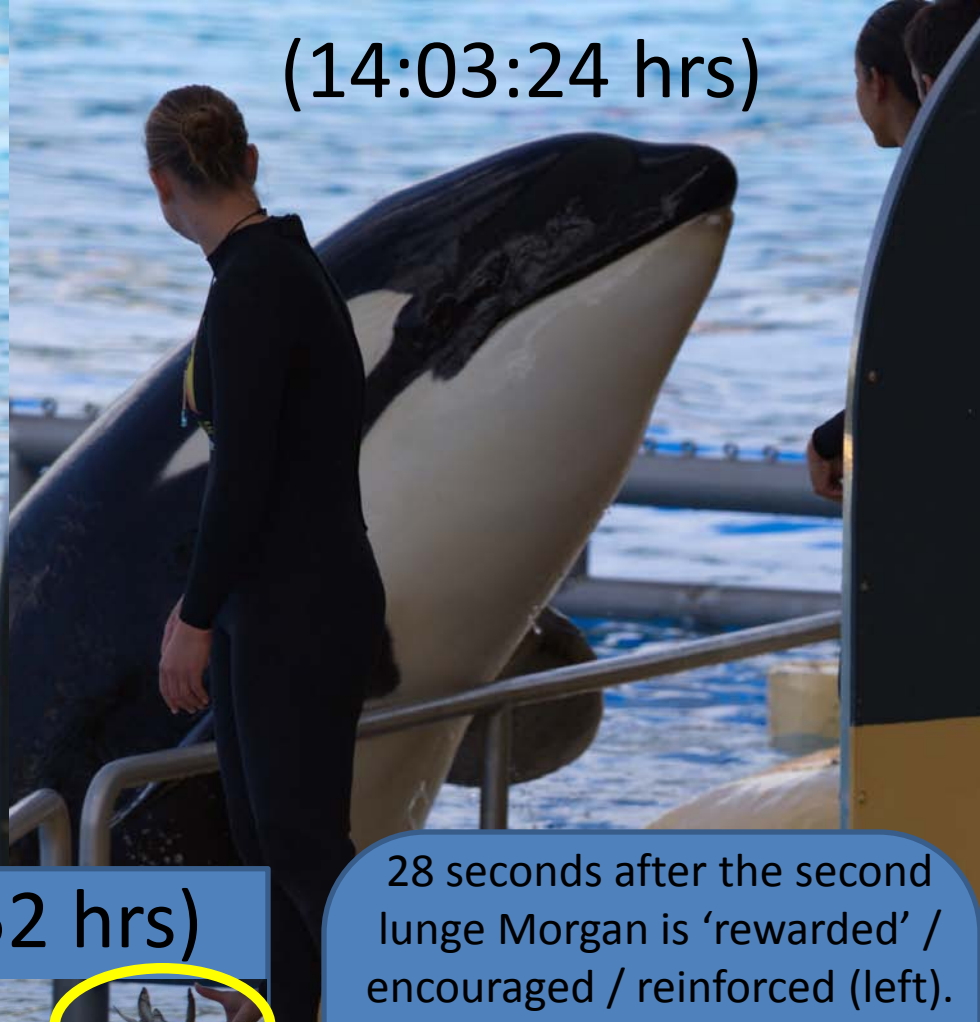Morgan beginning to lunge – not she is against the ‘safety rail. The position of trainer beside her could result in Morgan easily grabbing him if she rolled to the side (NOTE ‘normal’ position of other orca’s at the rails, down low)



(14:03:14 hrs)



(14:03:24 hrs)

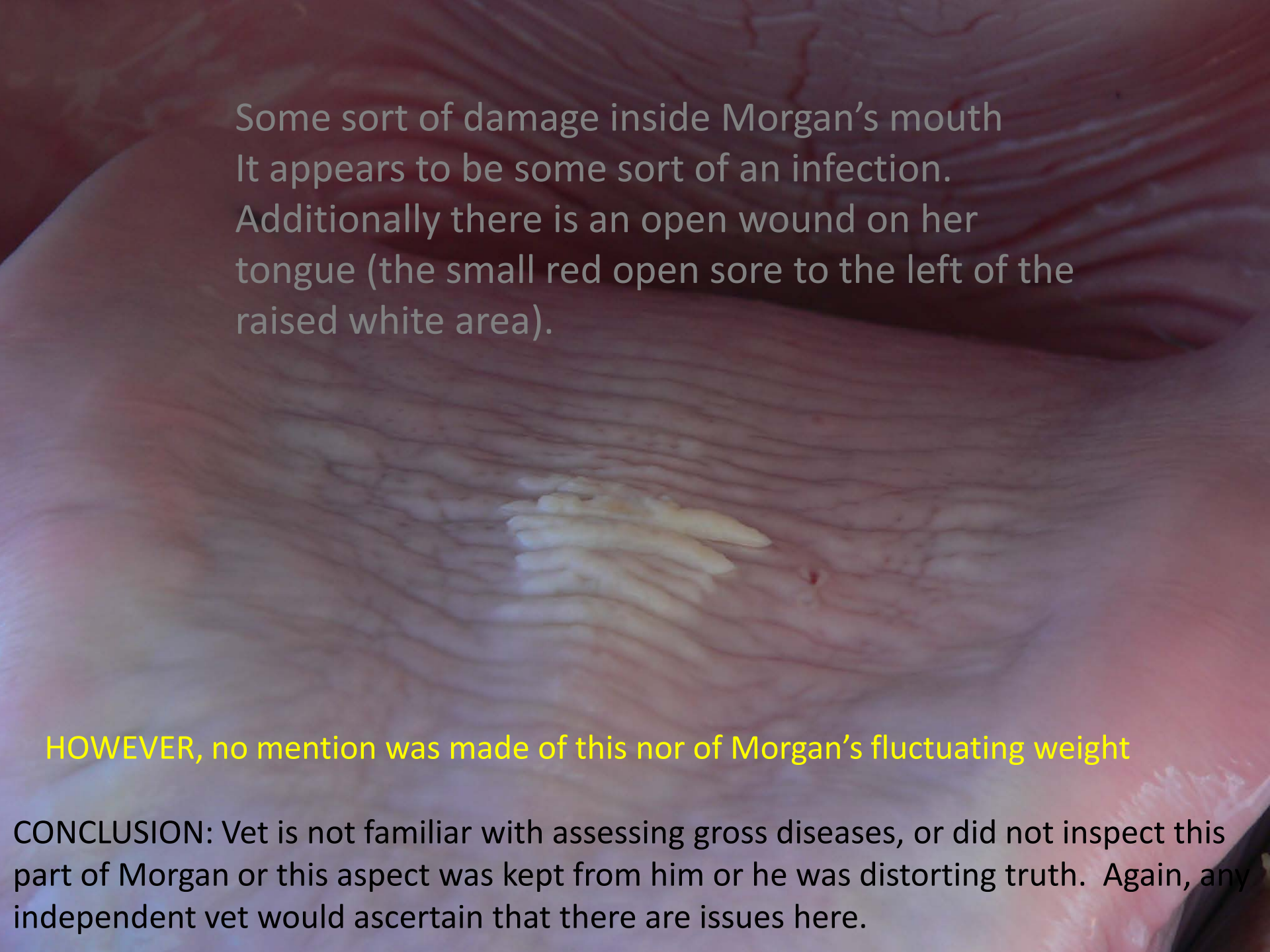


(14:03:52 hrs)



Trainer is not looking at Morgan (bad practice). Morgan has risen up so high that she could easily hurt herself or trainer.

28 seconds after the second lunge Morgan is 'rewarded' / encouraged / reinforced (left). Because this is done after the lunge, she perceives the reward as given for lunging, rather than the actual behaviour she had been 'asked' to do (i.e., this is bad & very dangerous training)

A close-up photograph of a horse's tongue. The tongue is pink and shows a large, irregular white plaque on its surface. To the left of this plaque, there is a small, red, open sore. The background is dark and out of focus.

Some sort of damage inside Morgan's mouth
It appears to be some sort of an infection.
Additionally there is an open wound on her
tongue (the small red open sore to the left of the
raised white area).

























































HOWEVER, no mention was made of this nor of Morgan's fluctuating weight

CONCLUSION: Vet is not familiar with assessing gross diseases, or did not inspect this part of Morgan or this aspect was kept from him or he was distorting truth. Again, any independent vet would ascertain that there are issues here.



IN MED TANK

IN SHOW

DATE	PRE SHOW			DURING SHOW			AFTER SHOW		
2013	1	2	3	1	2	3	1	2	3
5 Oct									
6 Oct									
7 Oct									
1 Nov									
2 Nov									
17 Nov									
18 Nov									
19 Nov									
22 Nov									



No observer



Visser present